X- RAYS

DR. KAMAL EL TOHAMI

PROFESSOR OF PEDIATRICS

CARDIOLOGY

CARDIOMEGALY

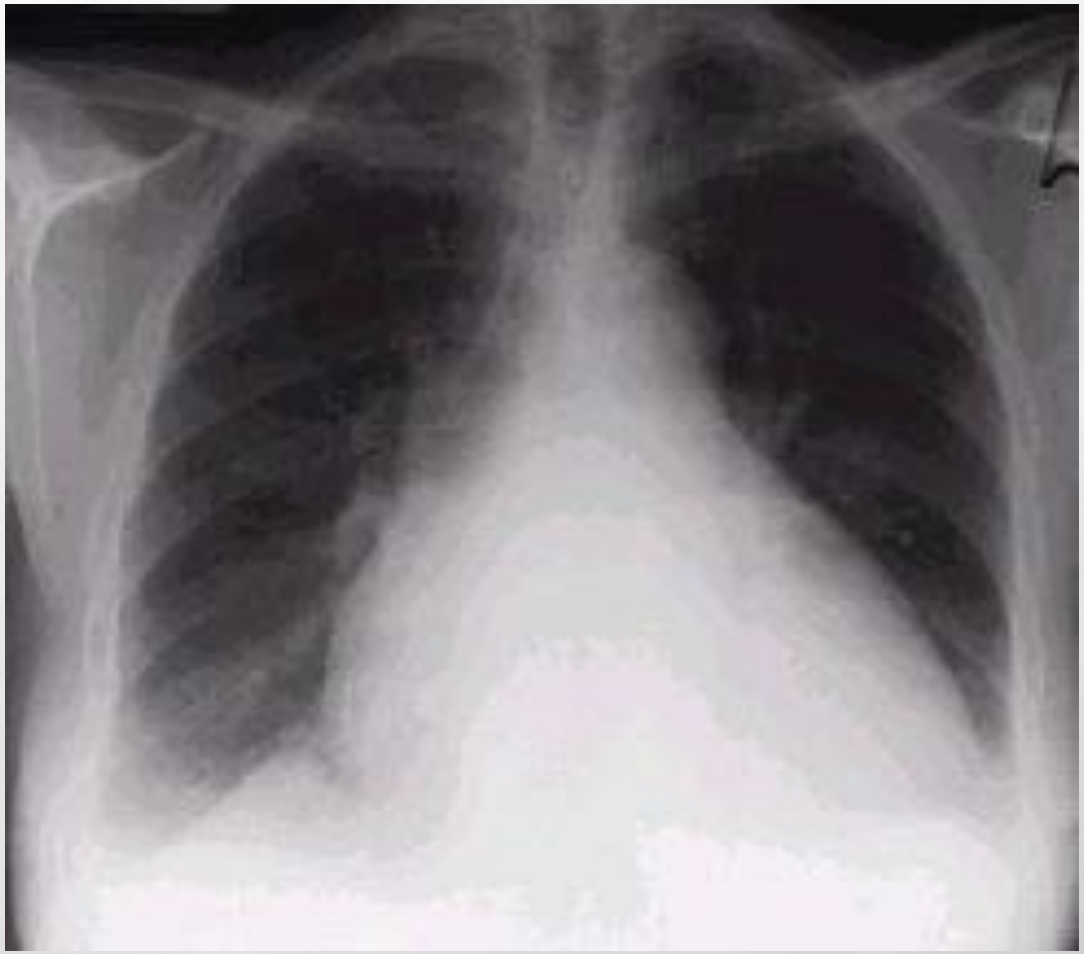

RIGHT VENTRICULAR HYPERTROPHY

DILATED CARDIOMYOPATHY

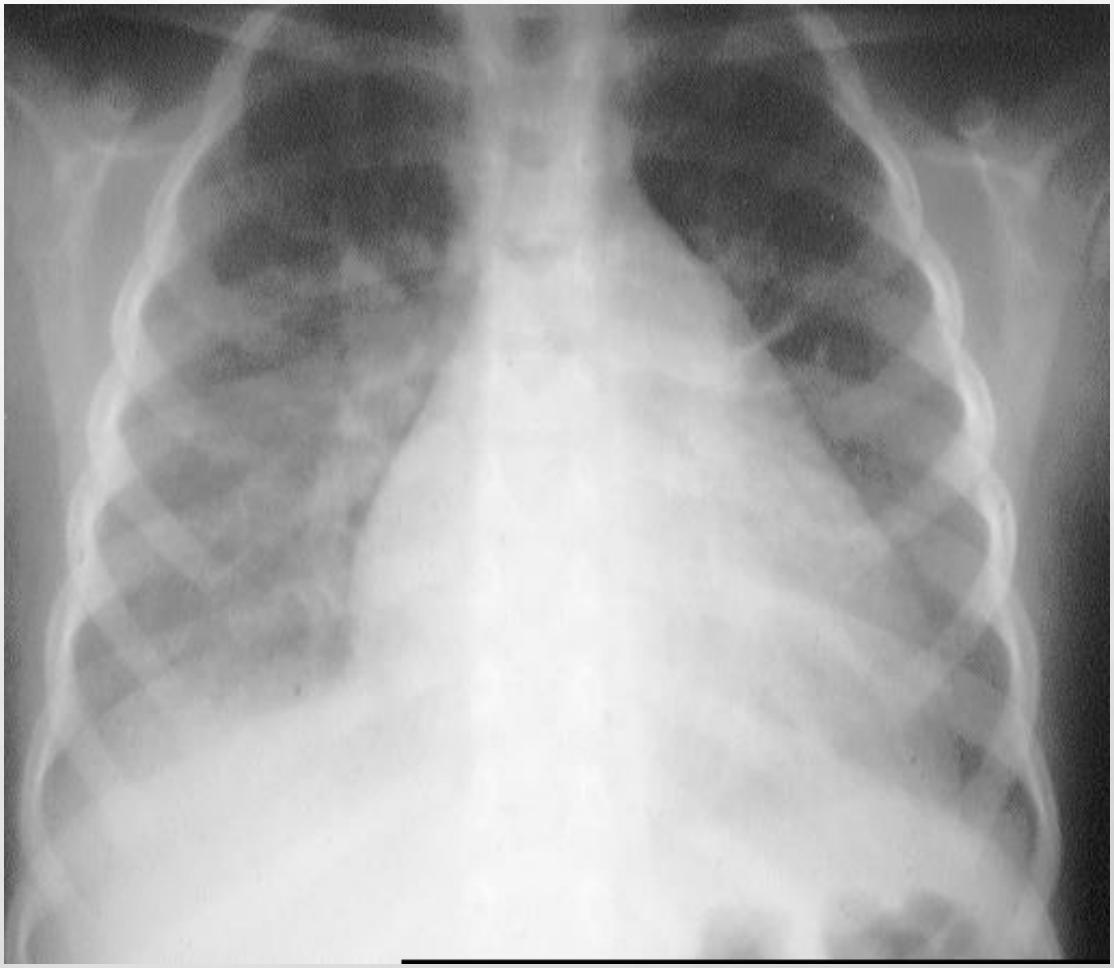

EPSTEIN ANOMALY

EGG ON SIDE TGA

PERICARDIAL EFFUSION

PERICARDIAL EFFUSION

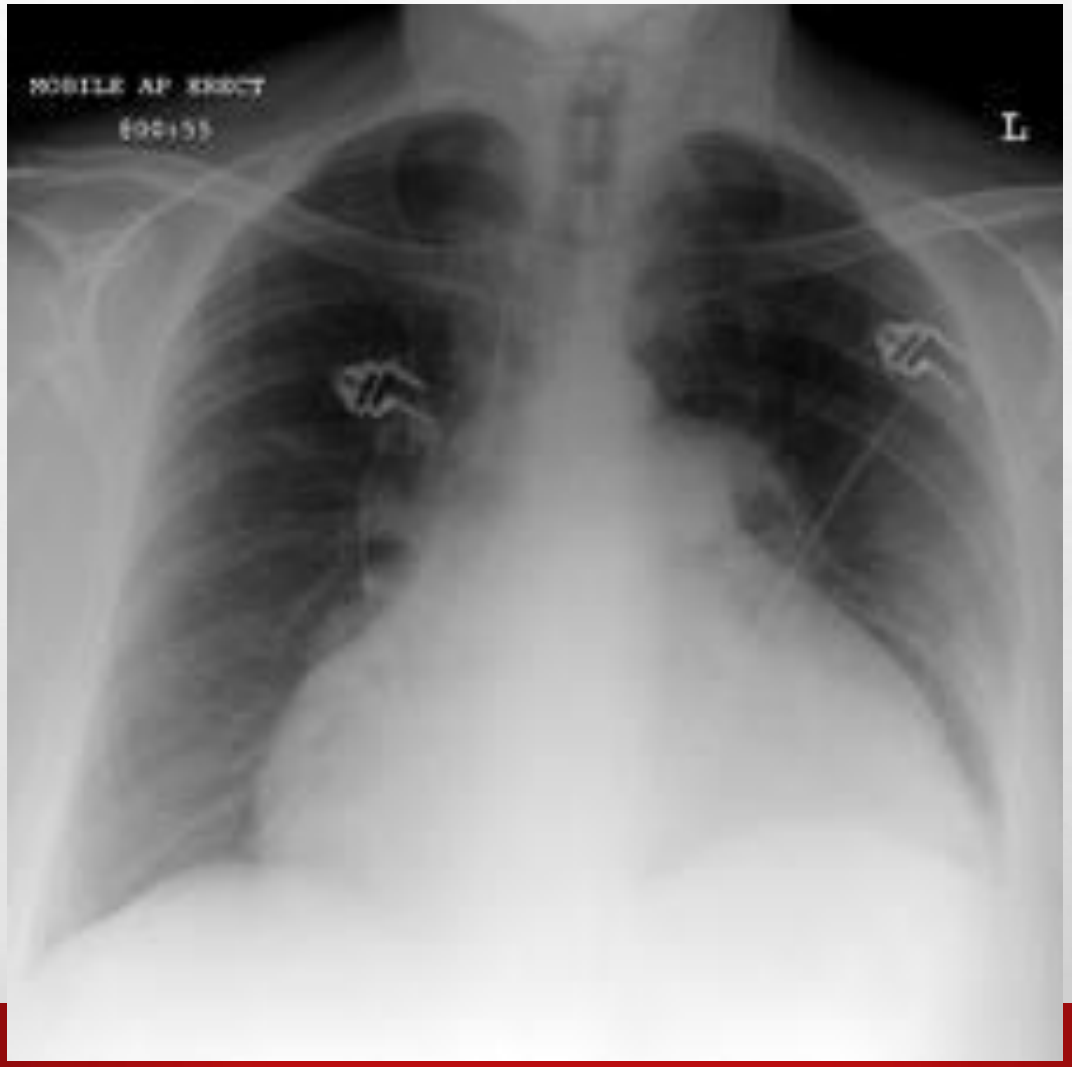

PERICARDITIS

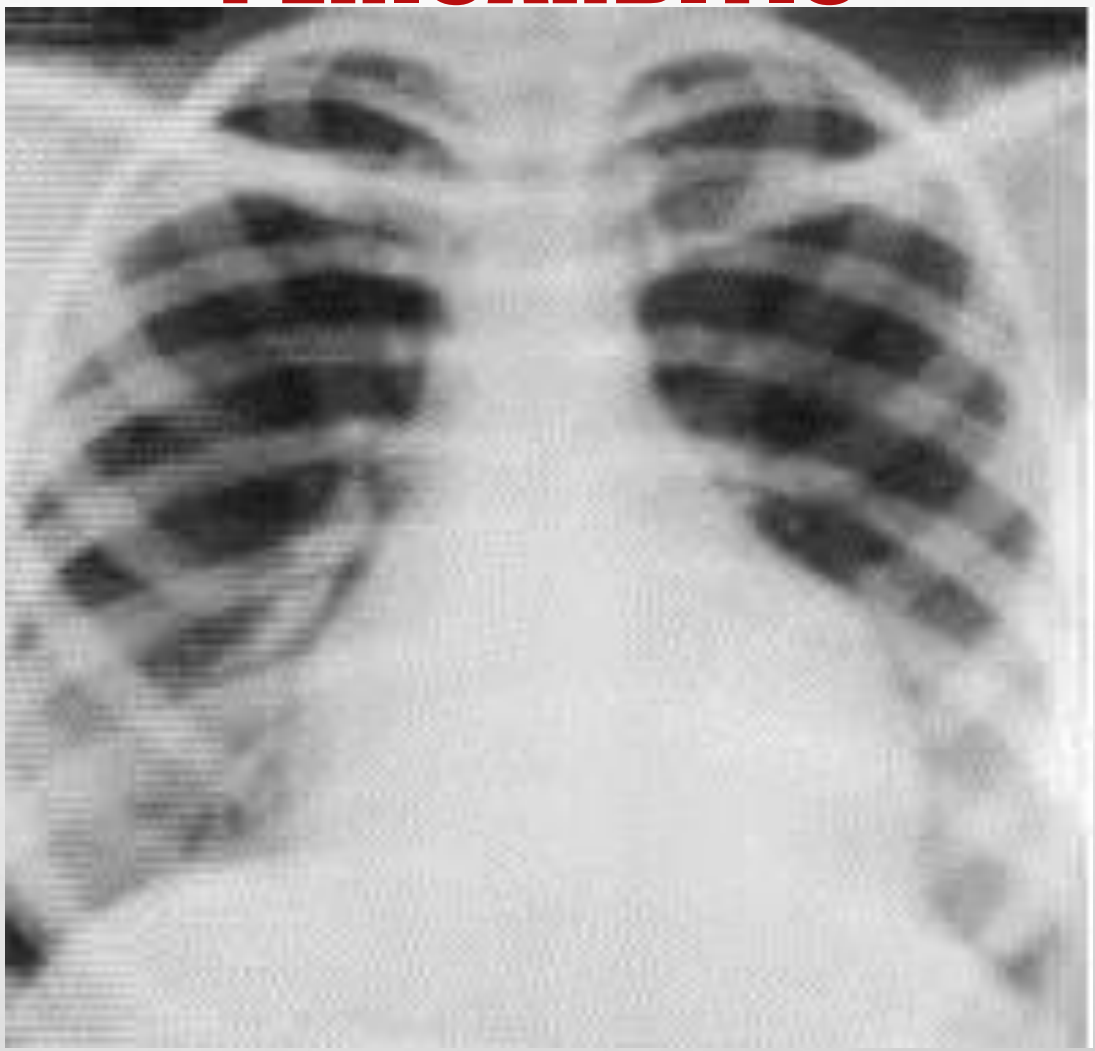

DEXTROCARDIA

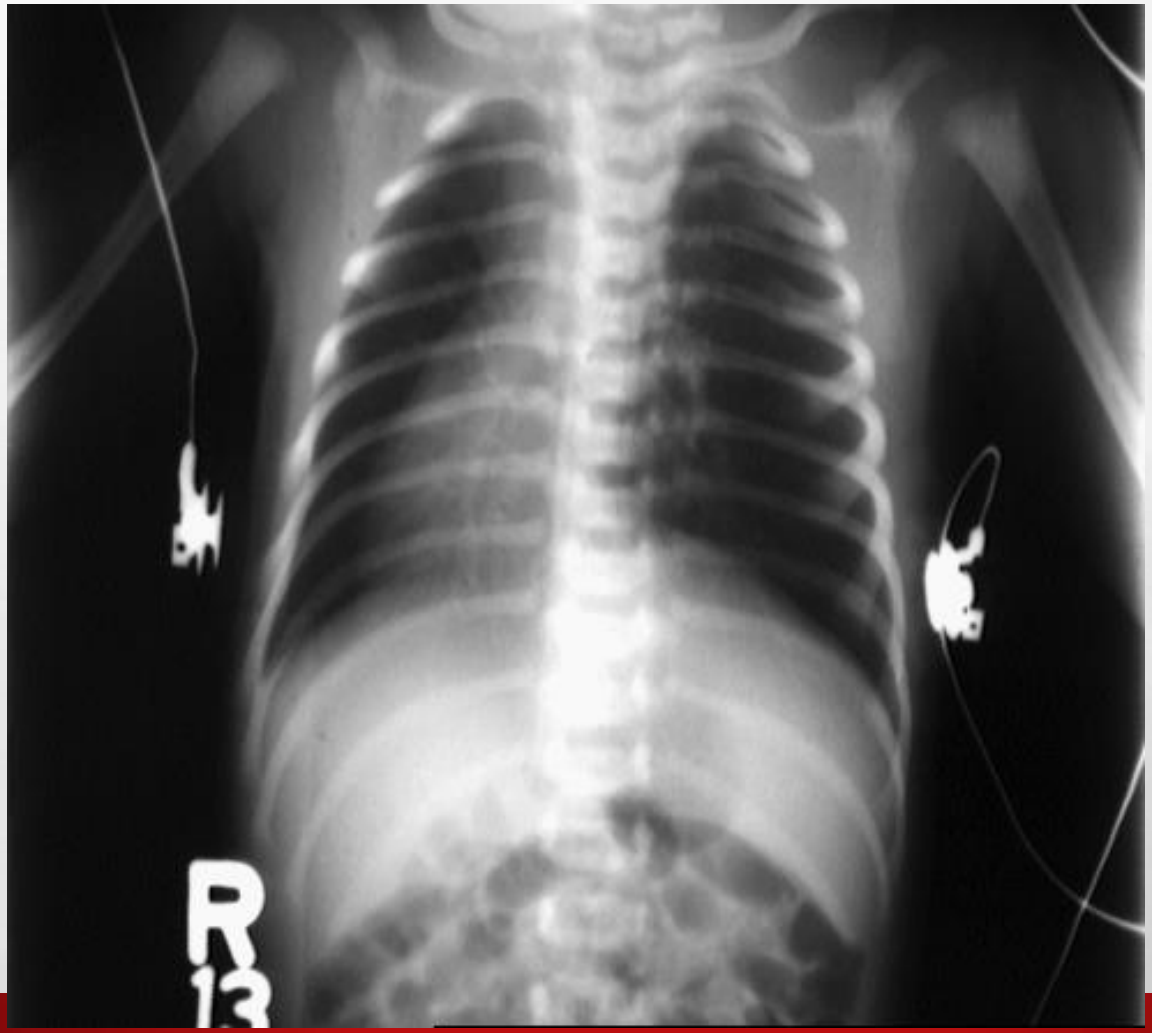

MITRAL STENOSIS

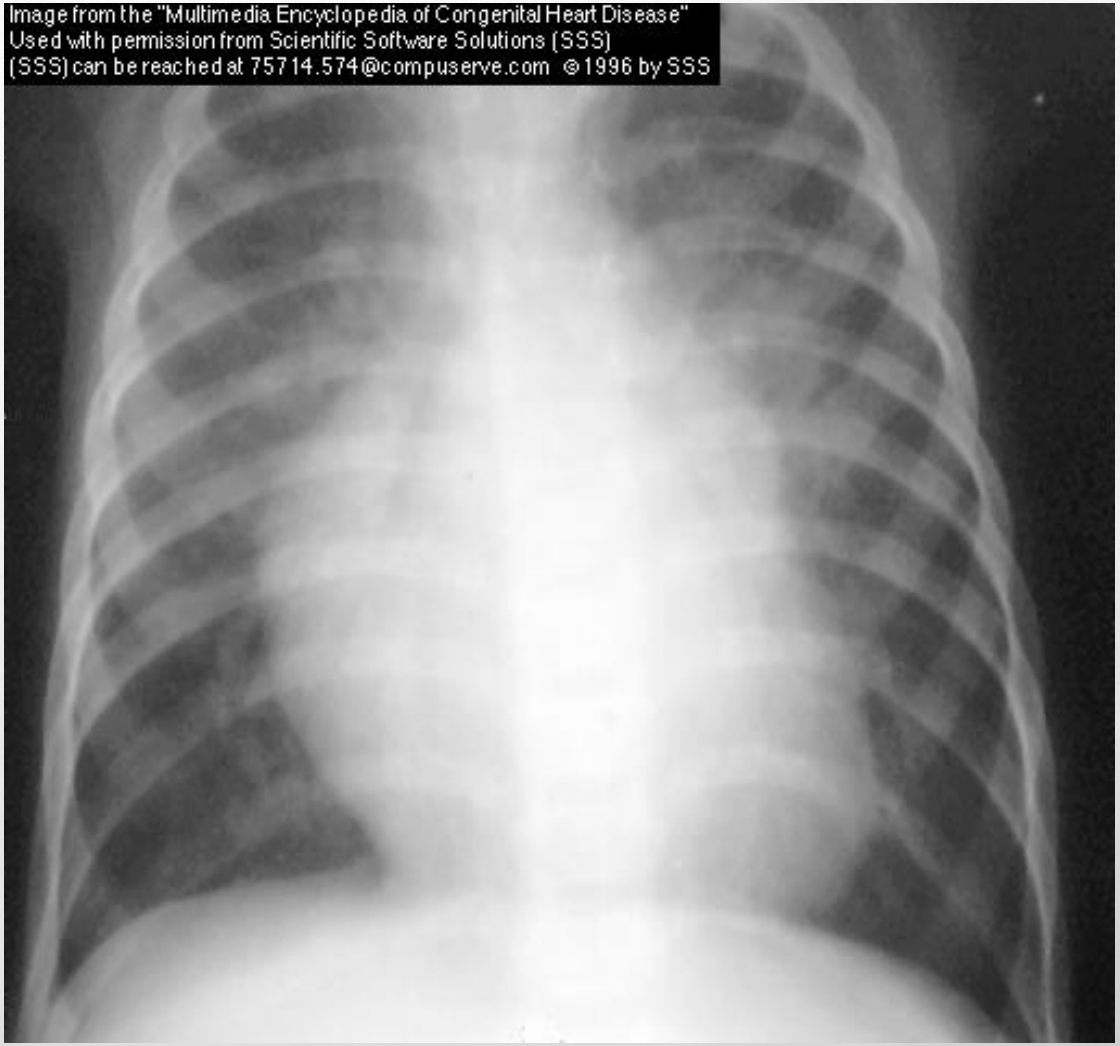

PULMONARY STENOSIS

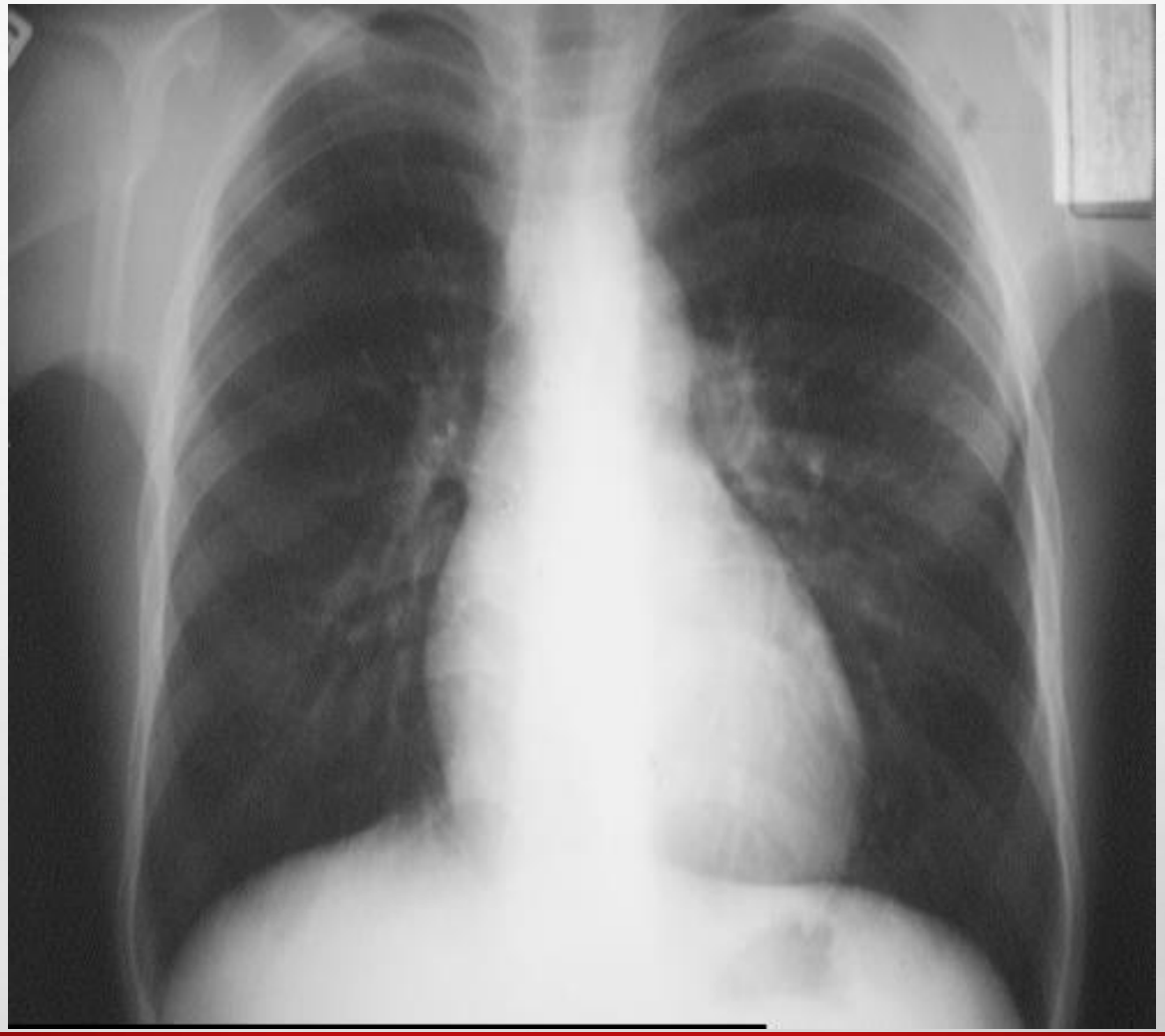

COARCTATION OF THE AORTA

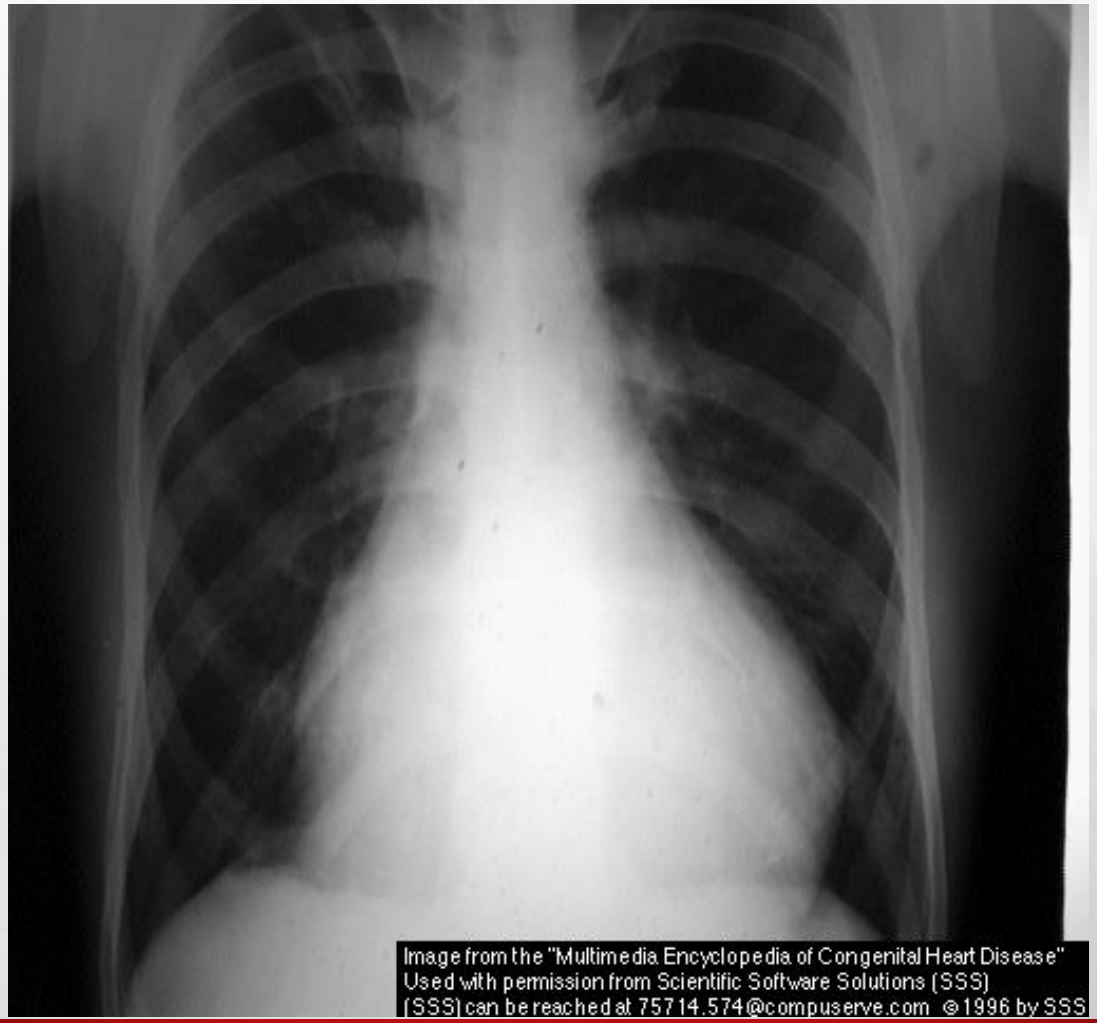

ASD

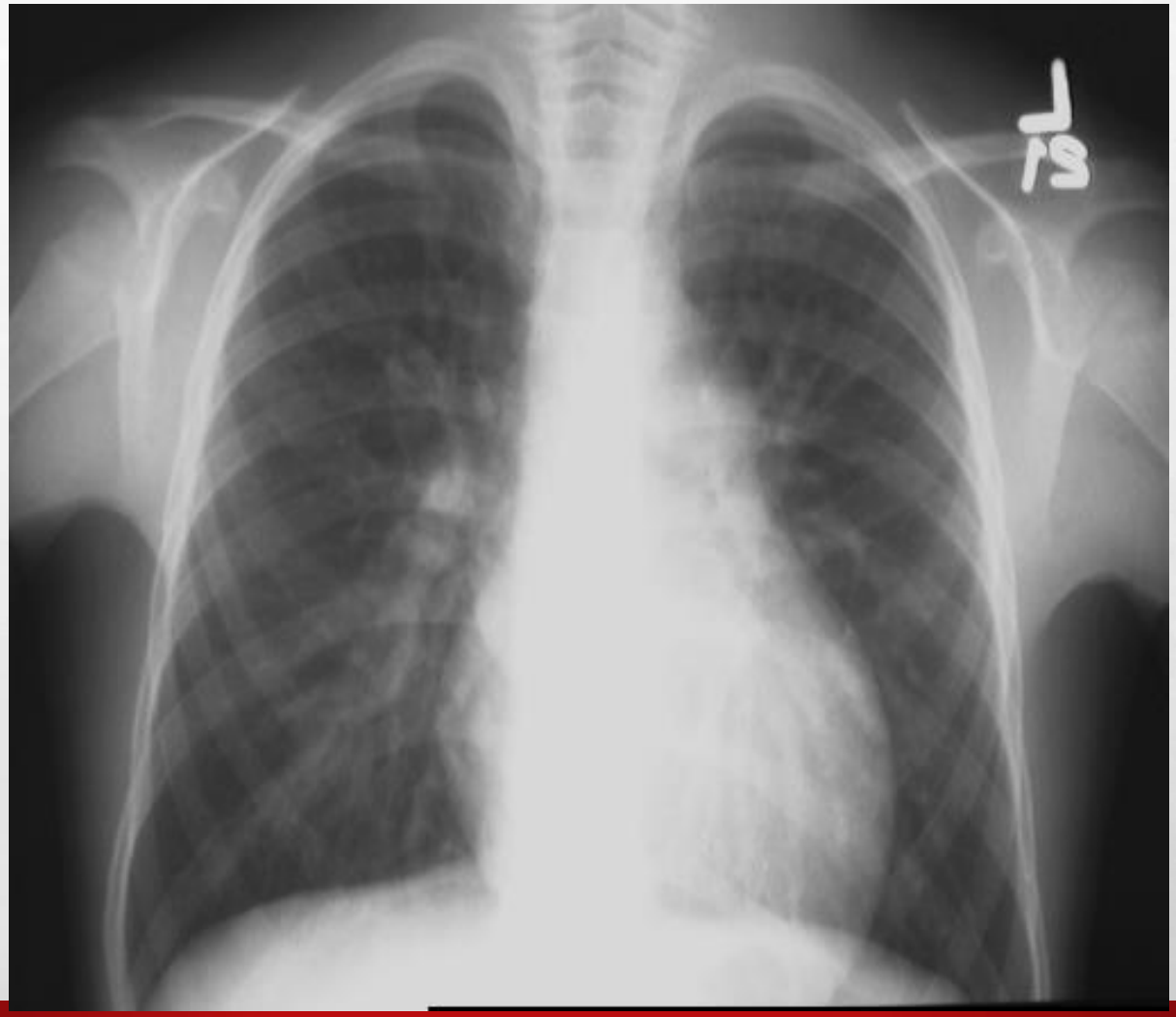

ASD

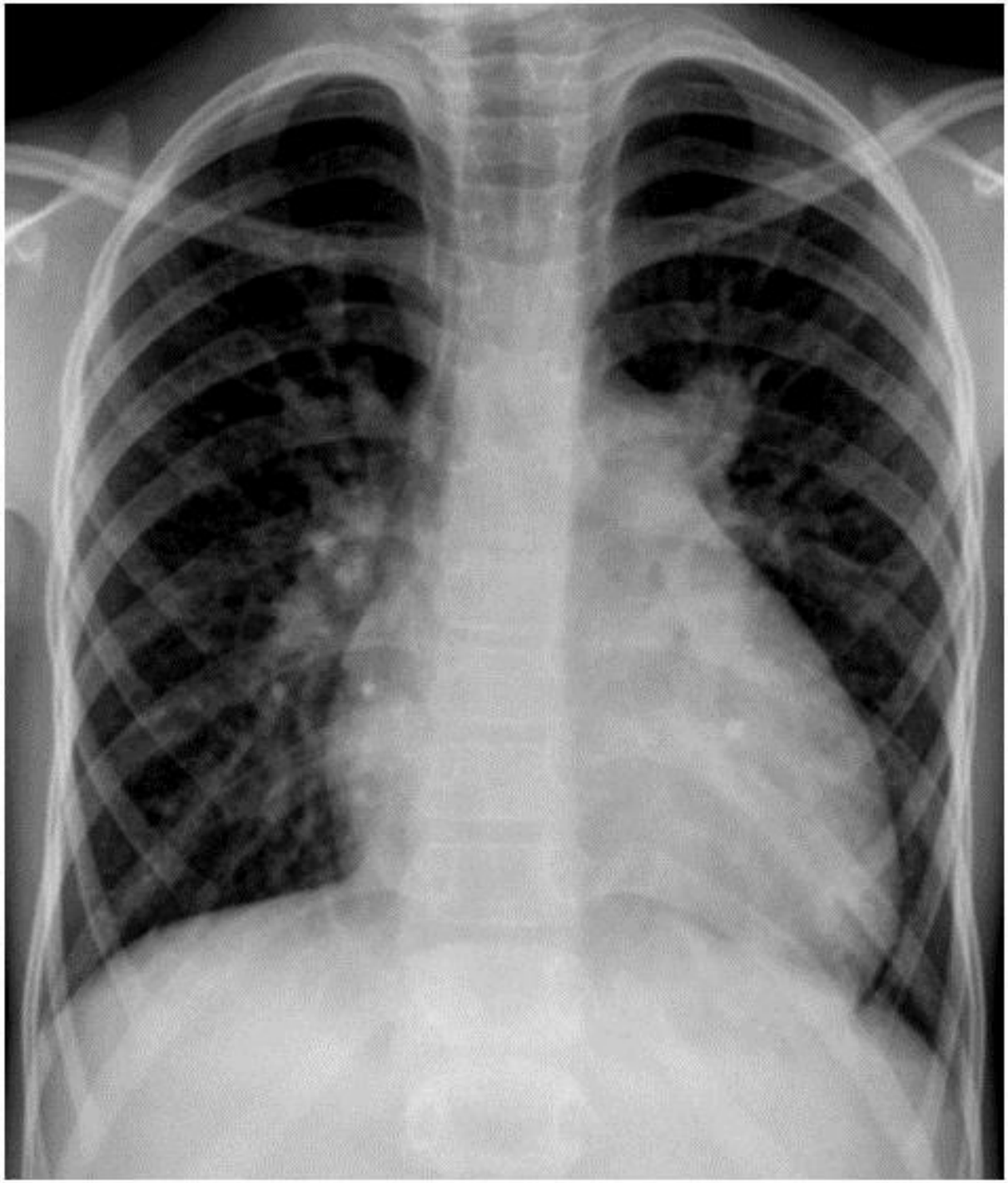

VSD

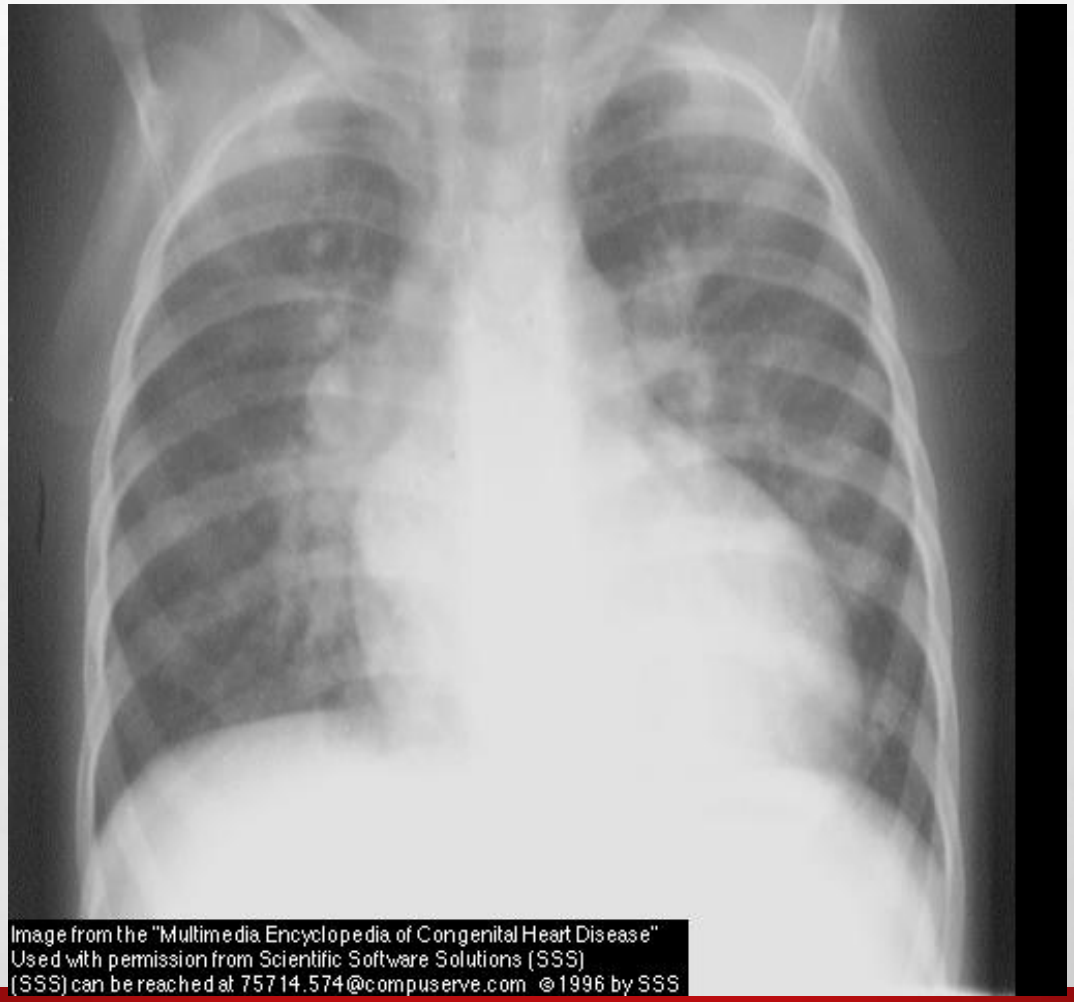
Image from the "Multimedia Encyclopedia of Congenital Heart Disease"
Used with permission from Scientific Software Solutions (SSS)
(SSS) can be reached at 75714.574@compuserve.com ©1996 by SSS

VSD

FALLOT'S

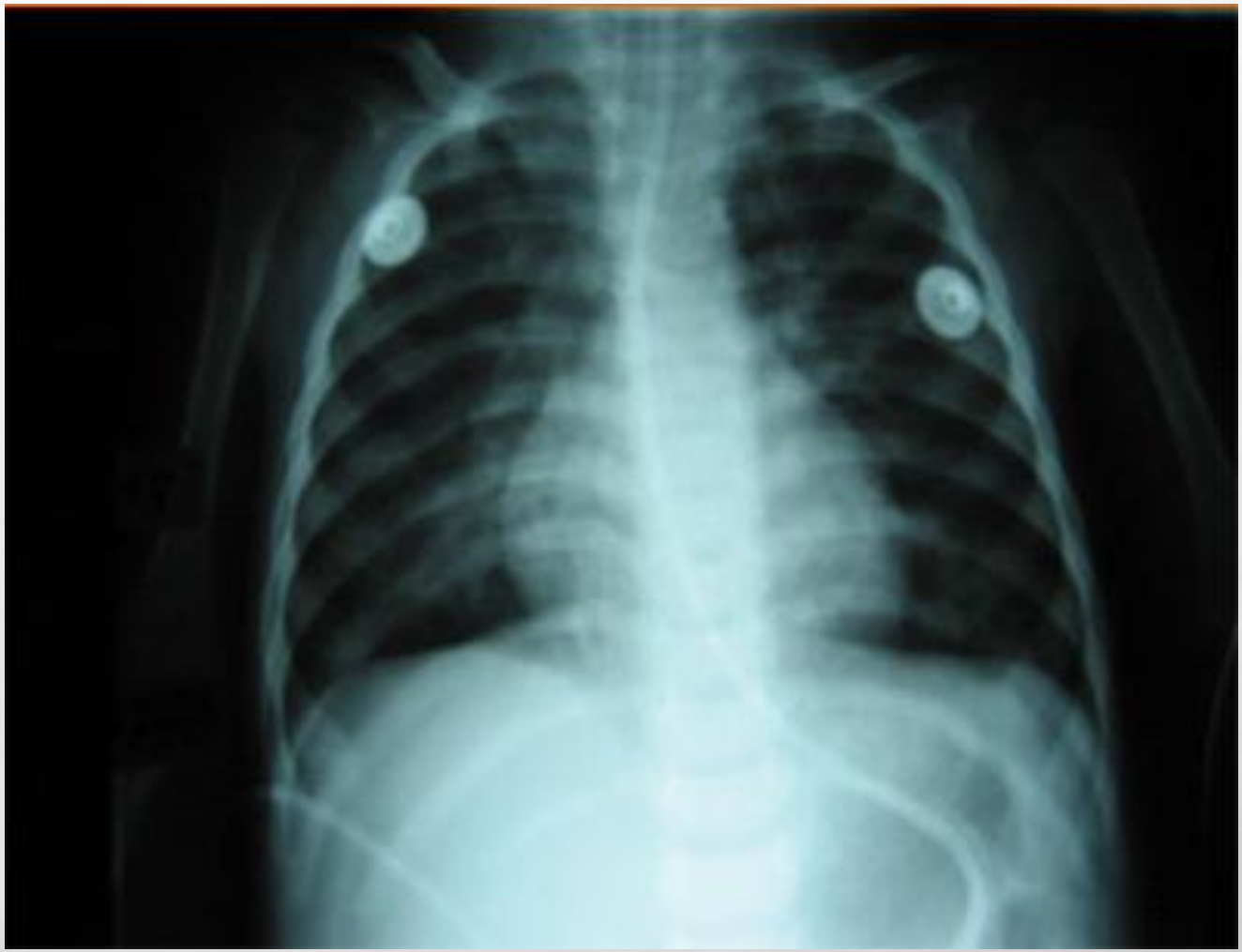

TETRALOGY OF FALLOT'S

CURE IN SABO BOOT SHAPE HEART

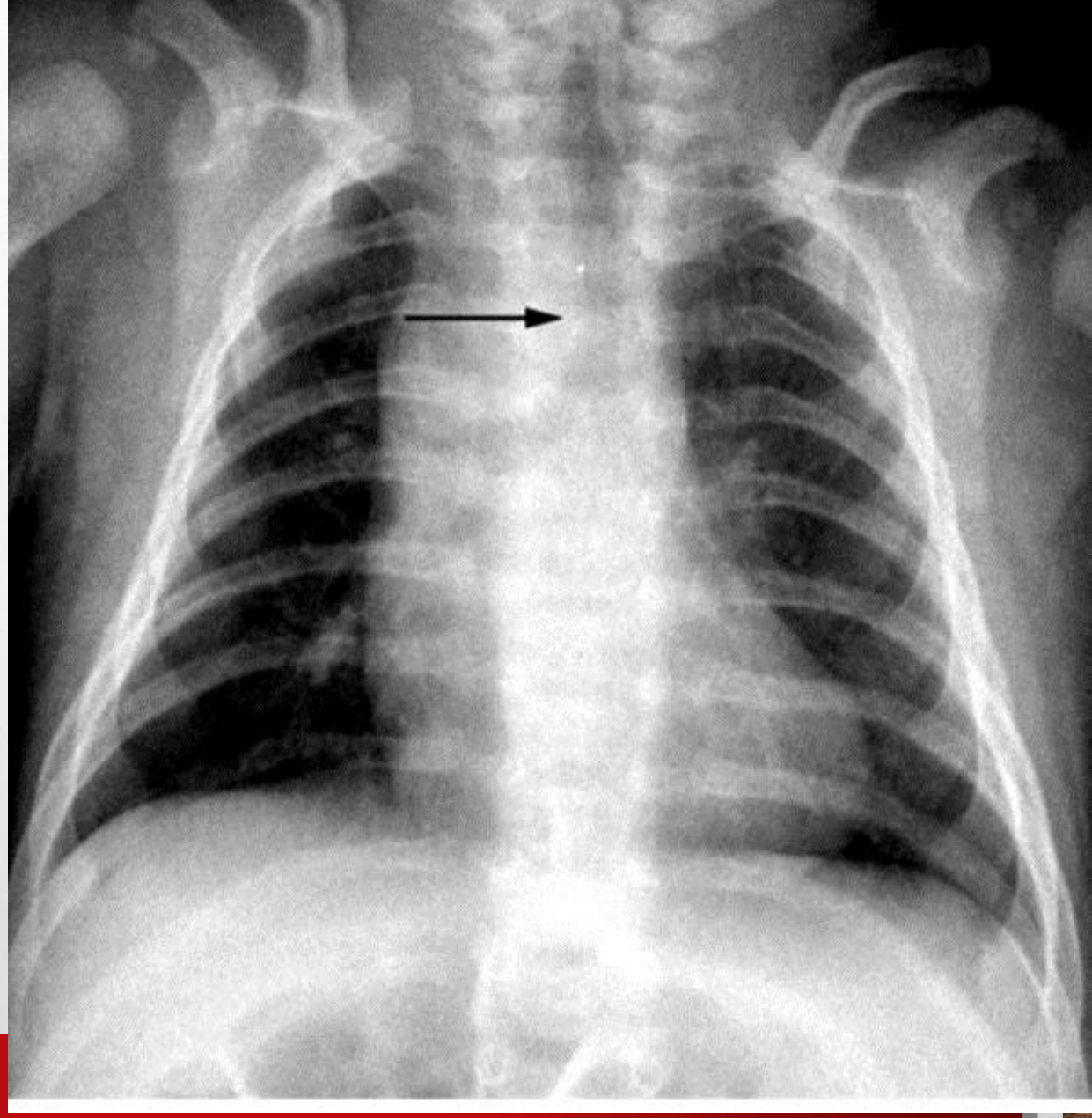

AS

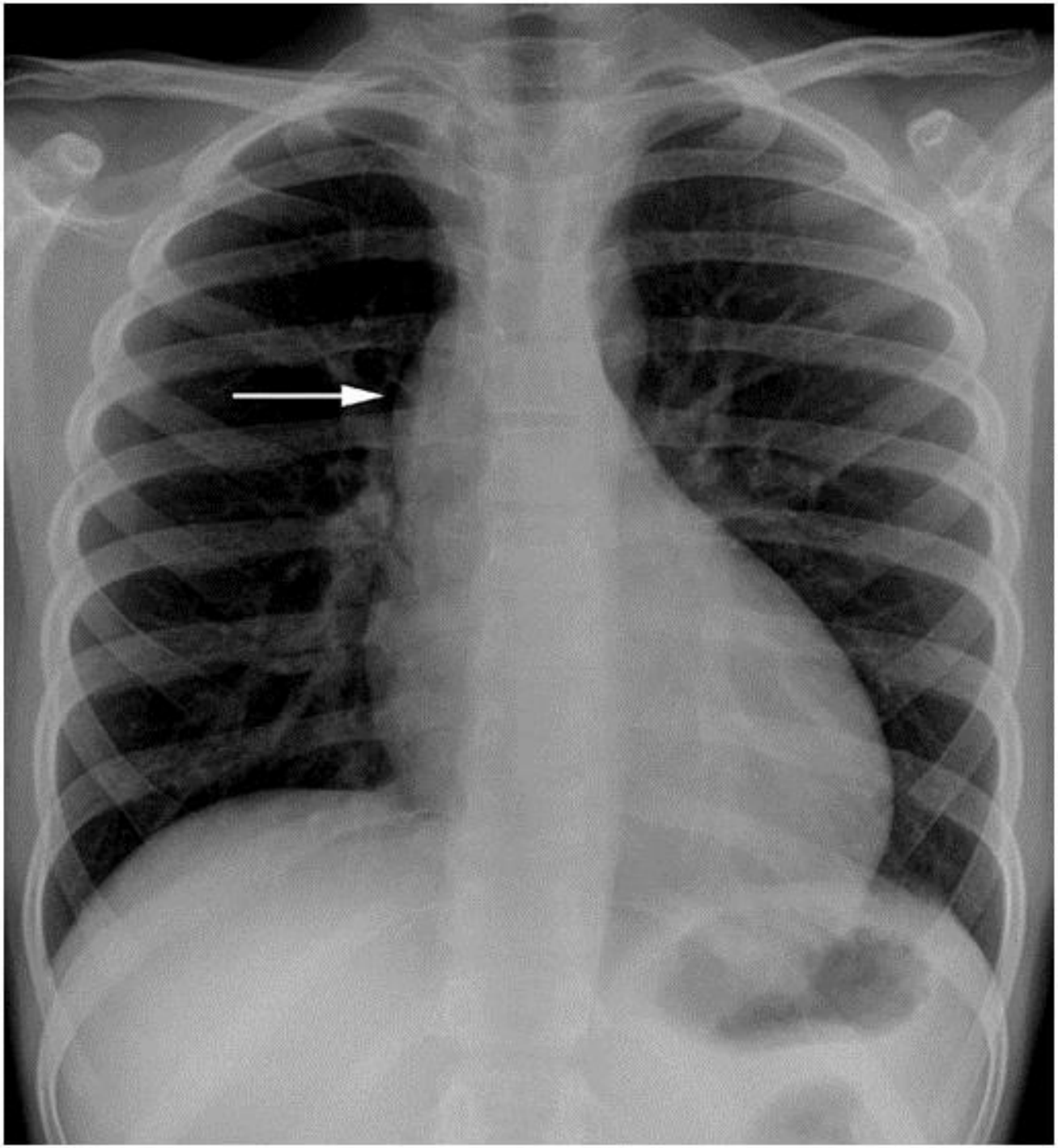

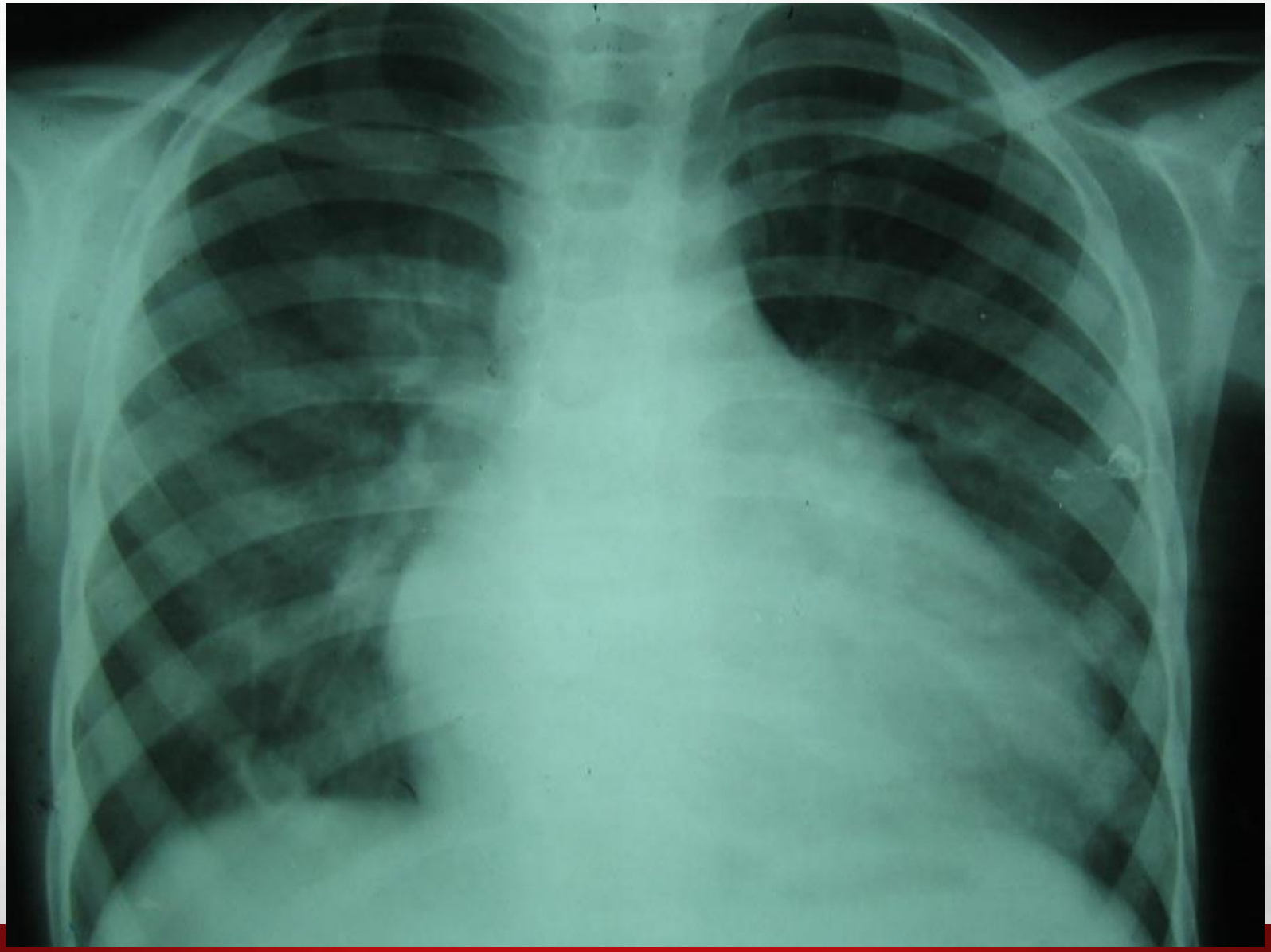

Loss of cardiac waist Mitralization

TGA EGG ON SIDE

TGA

R

DEXTROCARDIA

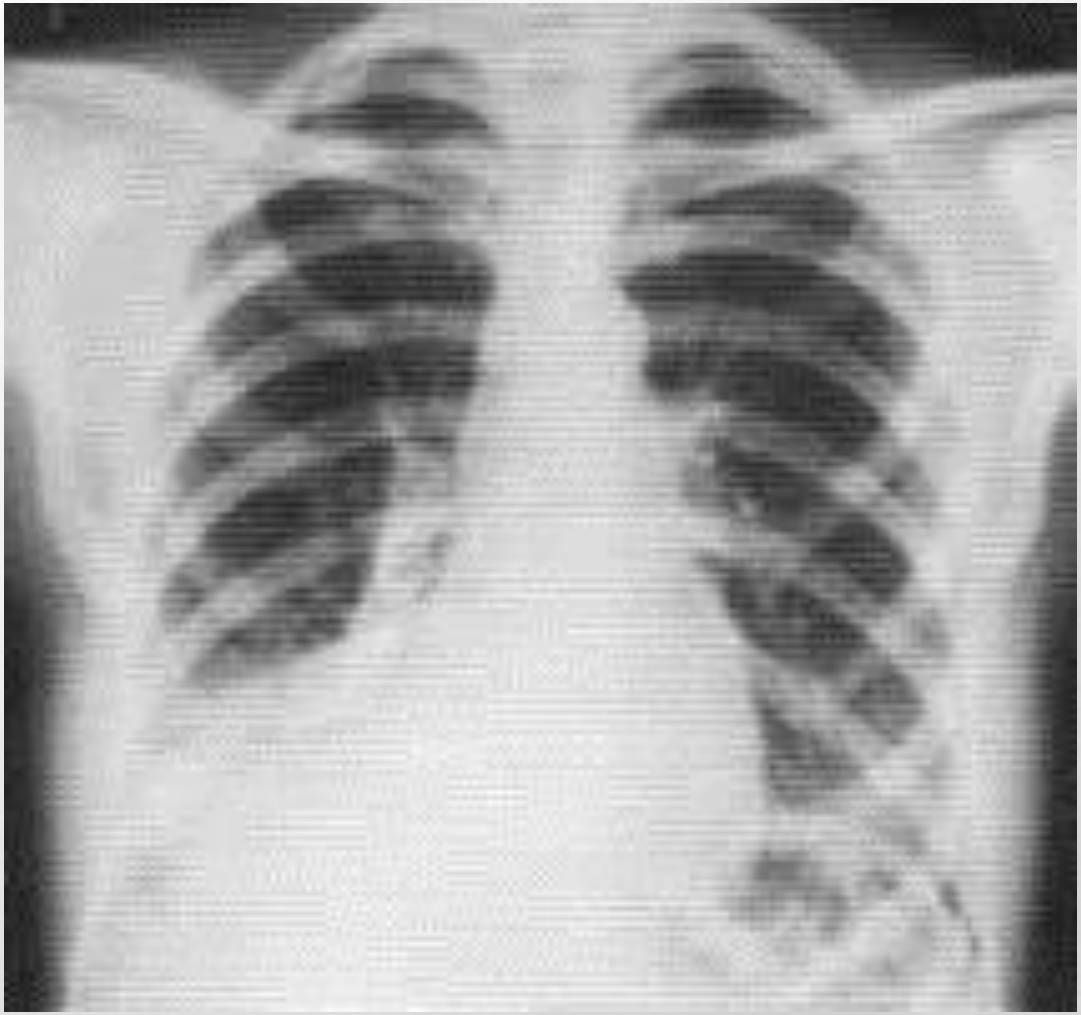

FLASK SHAPE HEART

PERICARDIAL EFFUSION

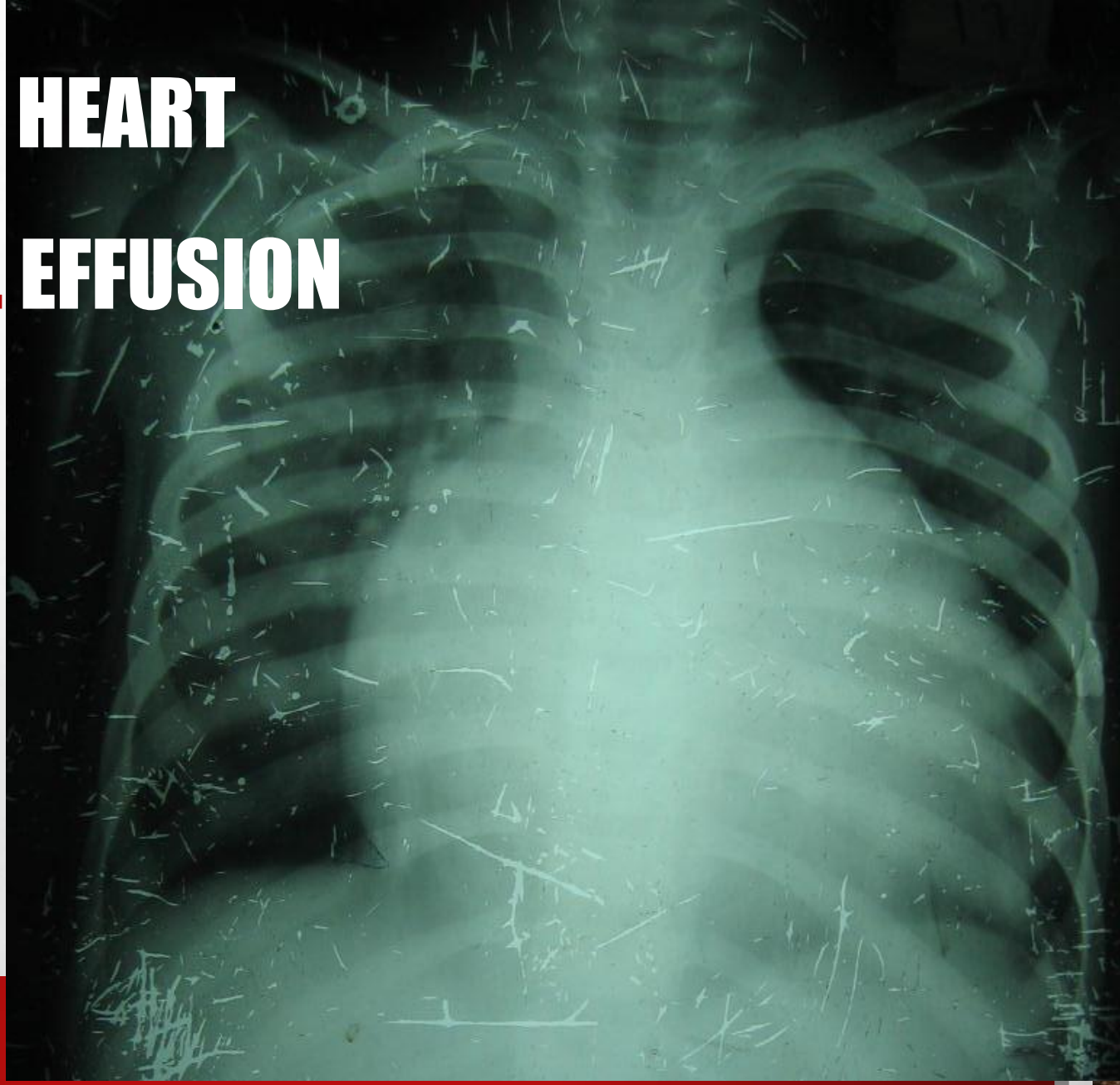

T
L.A
R.V
L.V.

CARDIOMEGALY

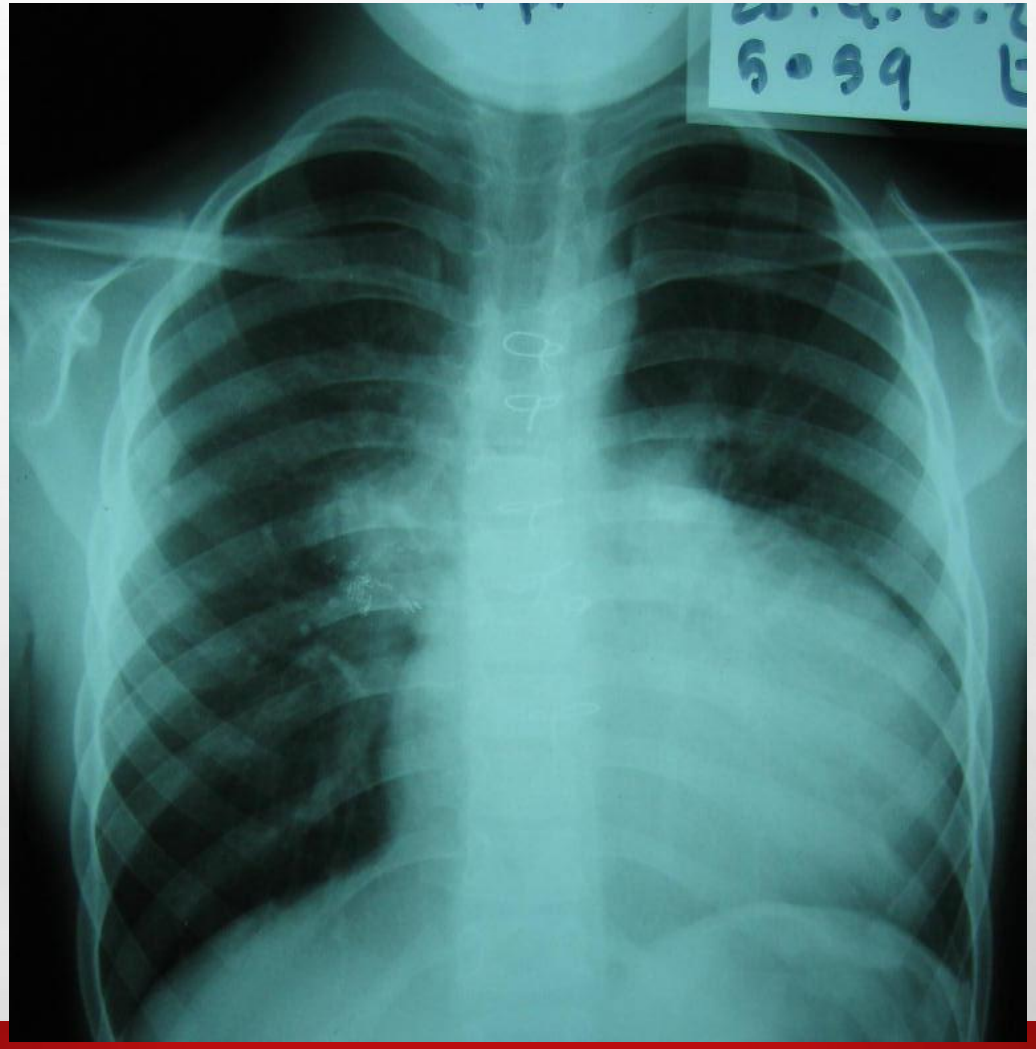

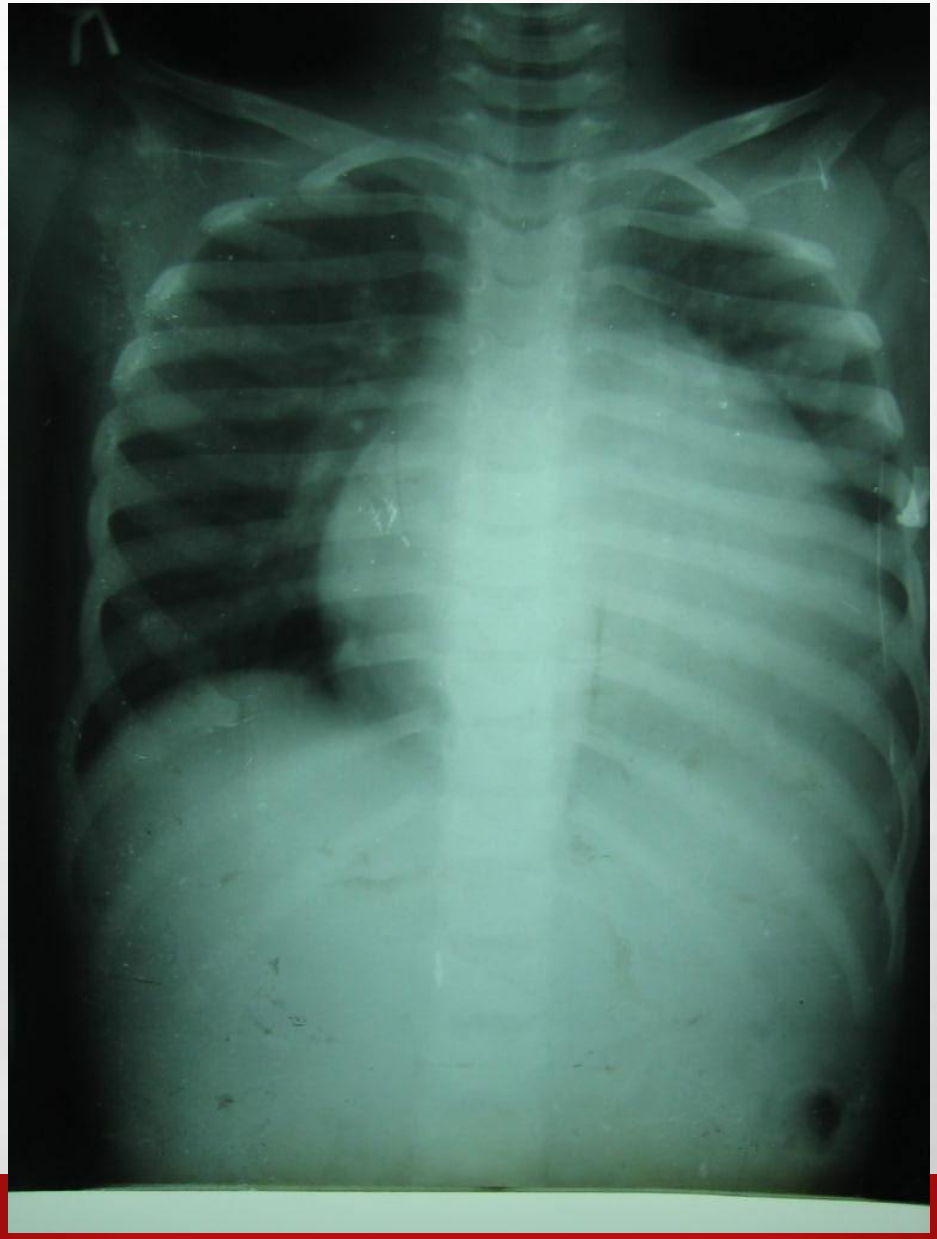

8 SHAPE HEART

PUL ATRESIA

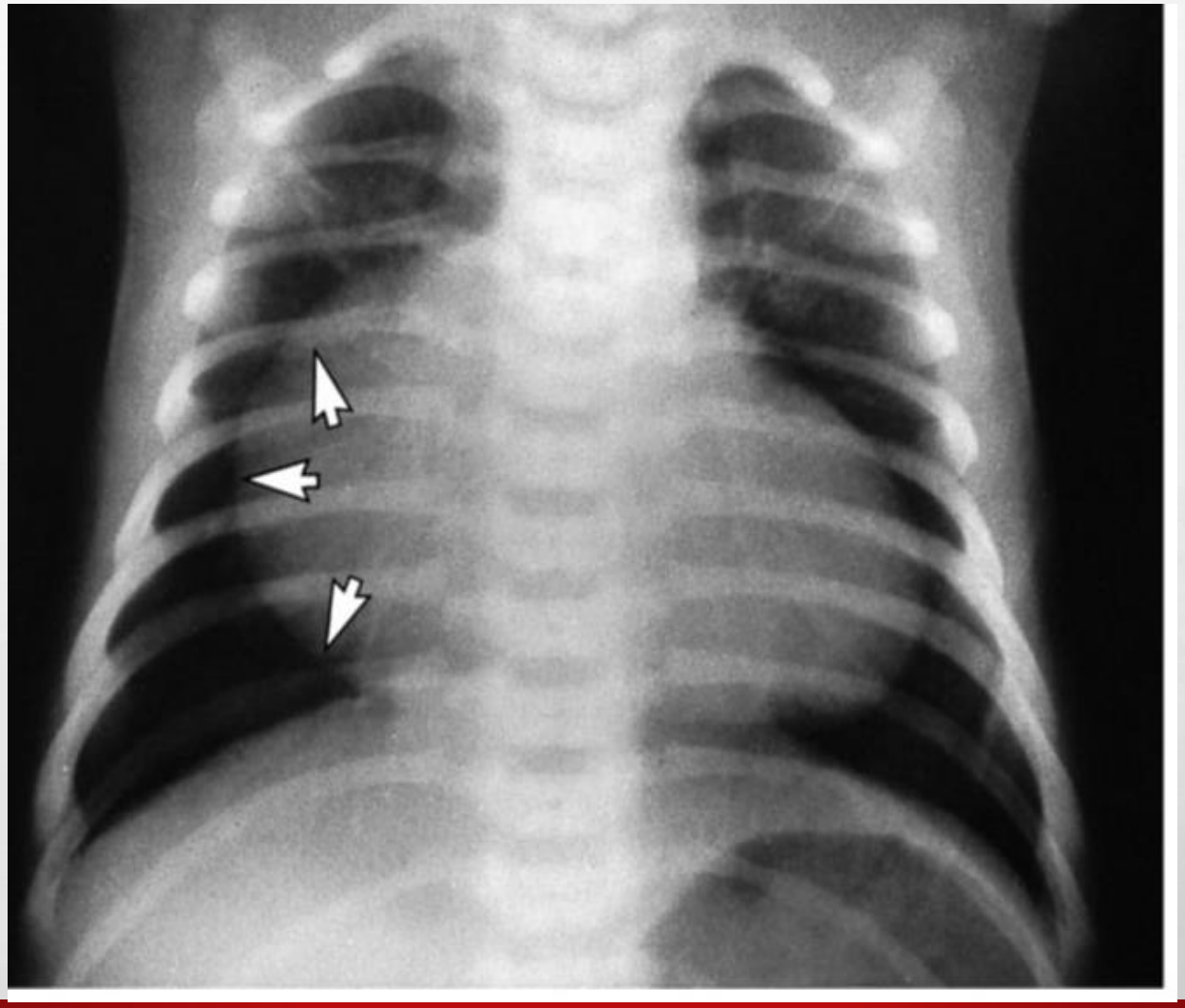

CHEST

RIGHT UPPER LOBAR PNEUMONIA

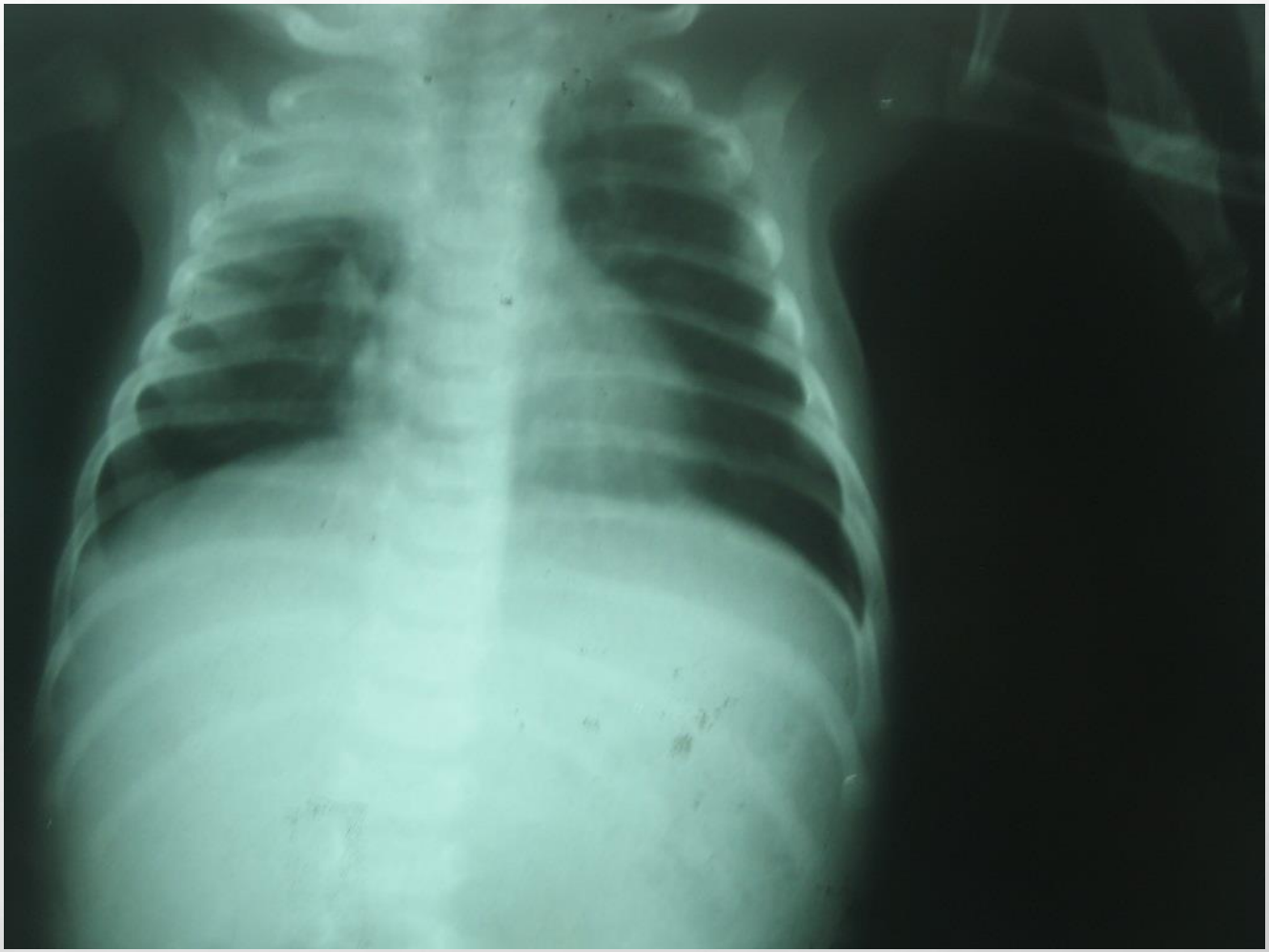

RIGHT UPPER LOBAR PNEUMONIA

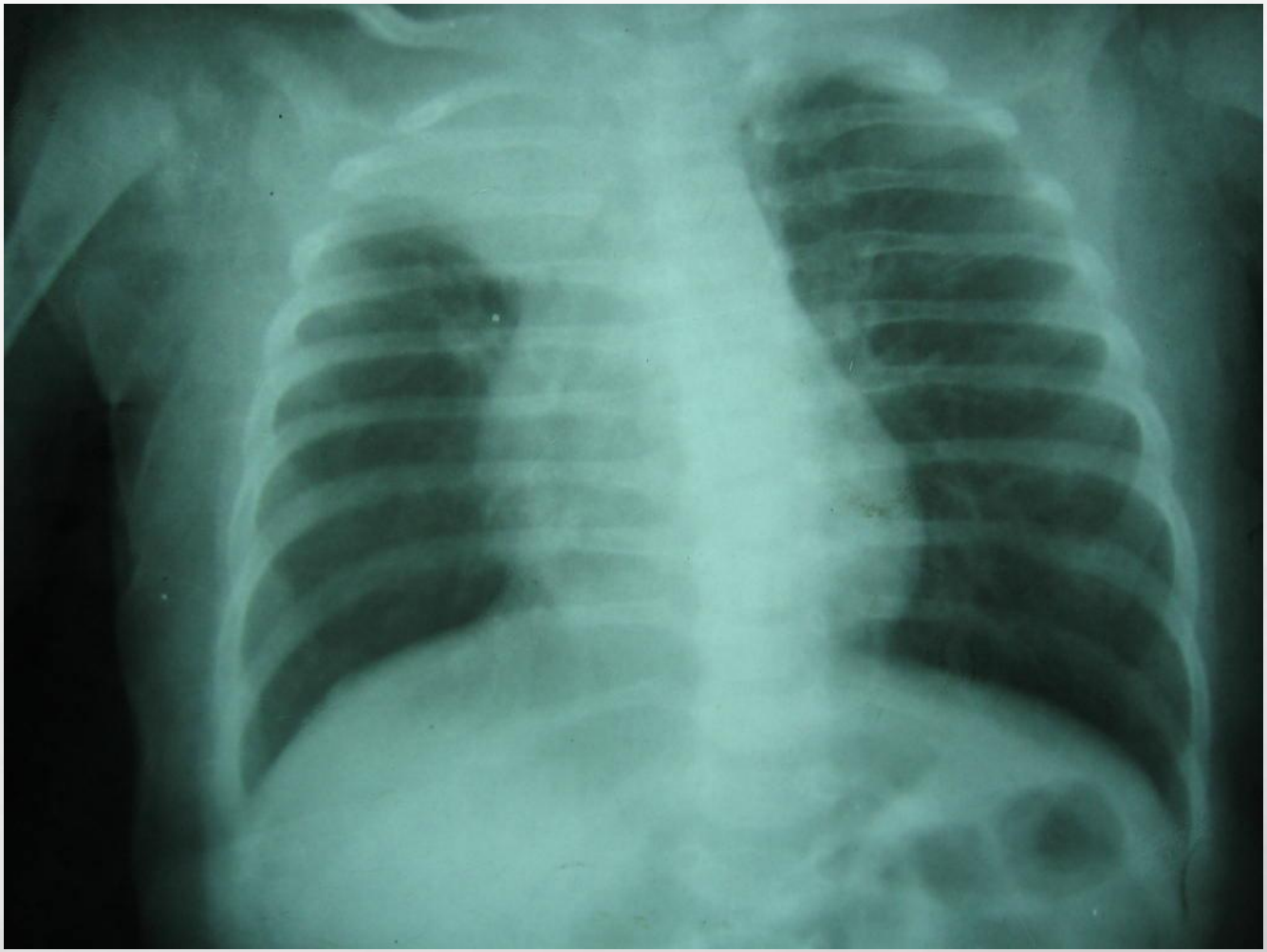

LOBAR PNEUMONIA

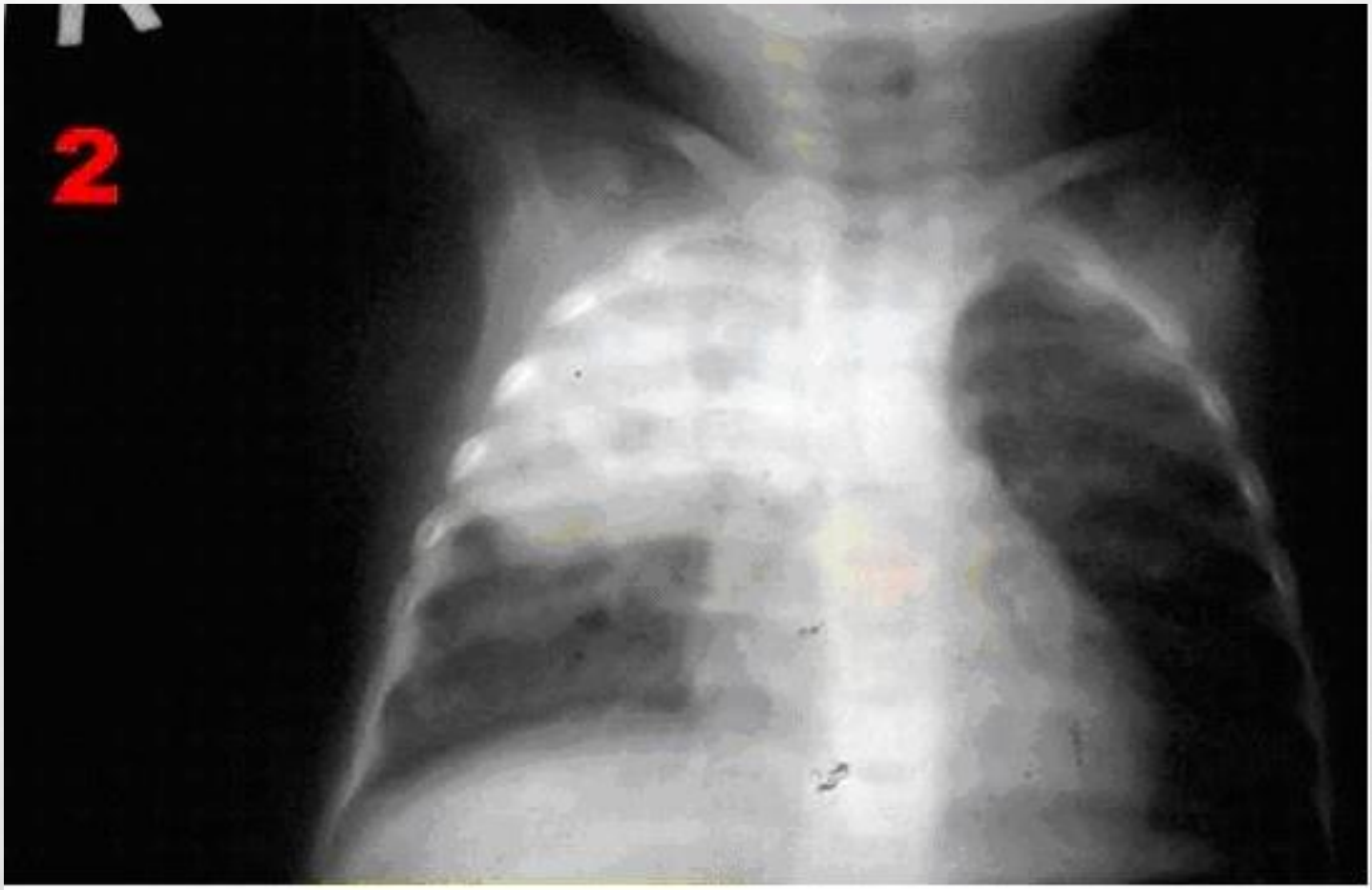

BRONCHOPNEUMONIA

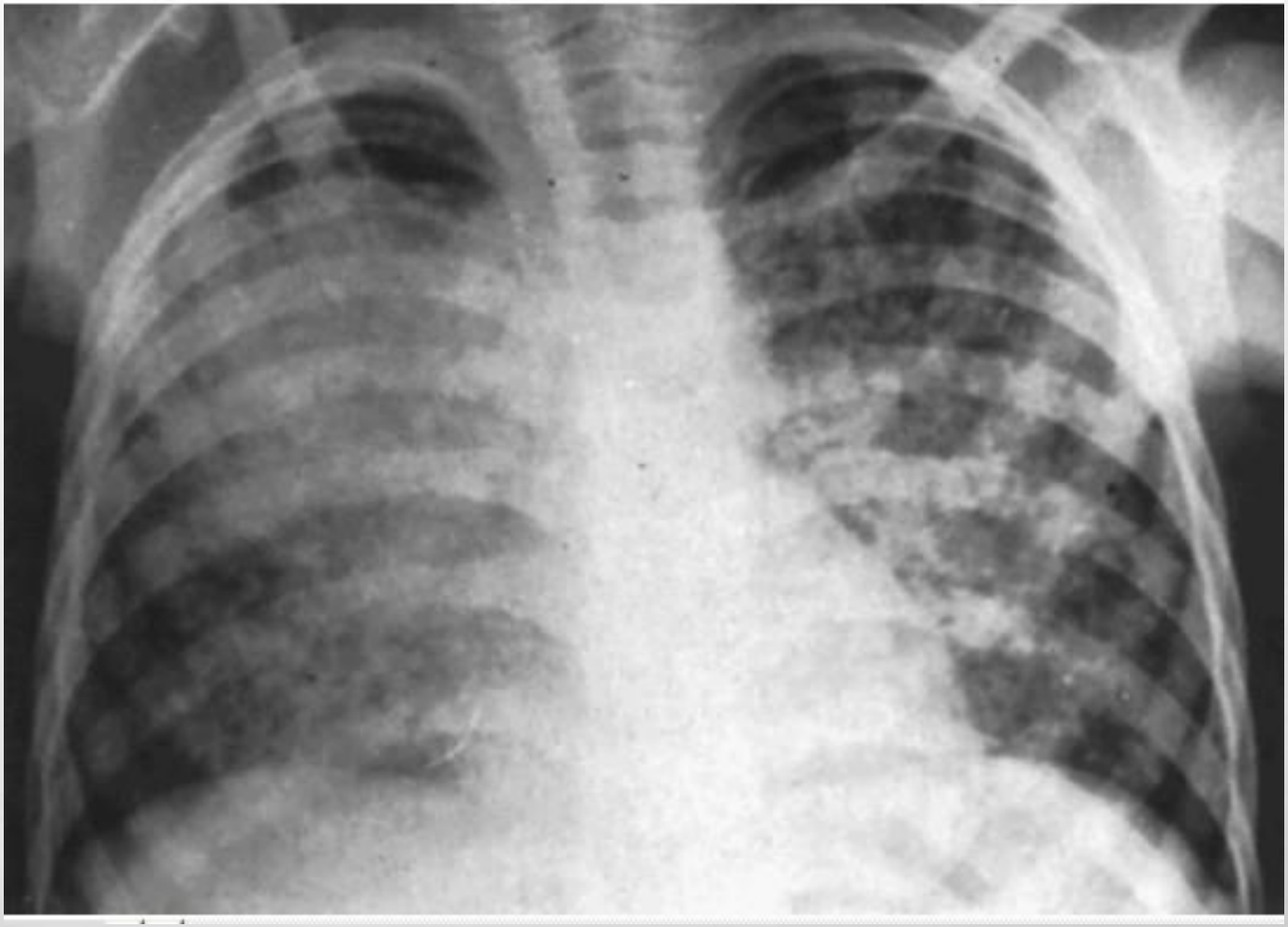

MIDDLE LOBAR PNEUMONIA

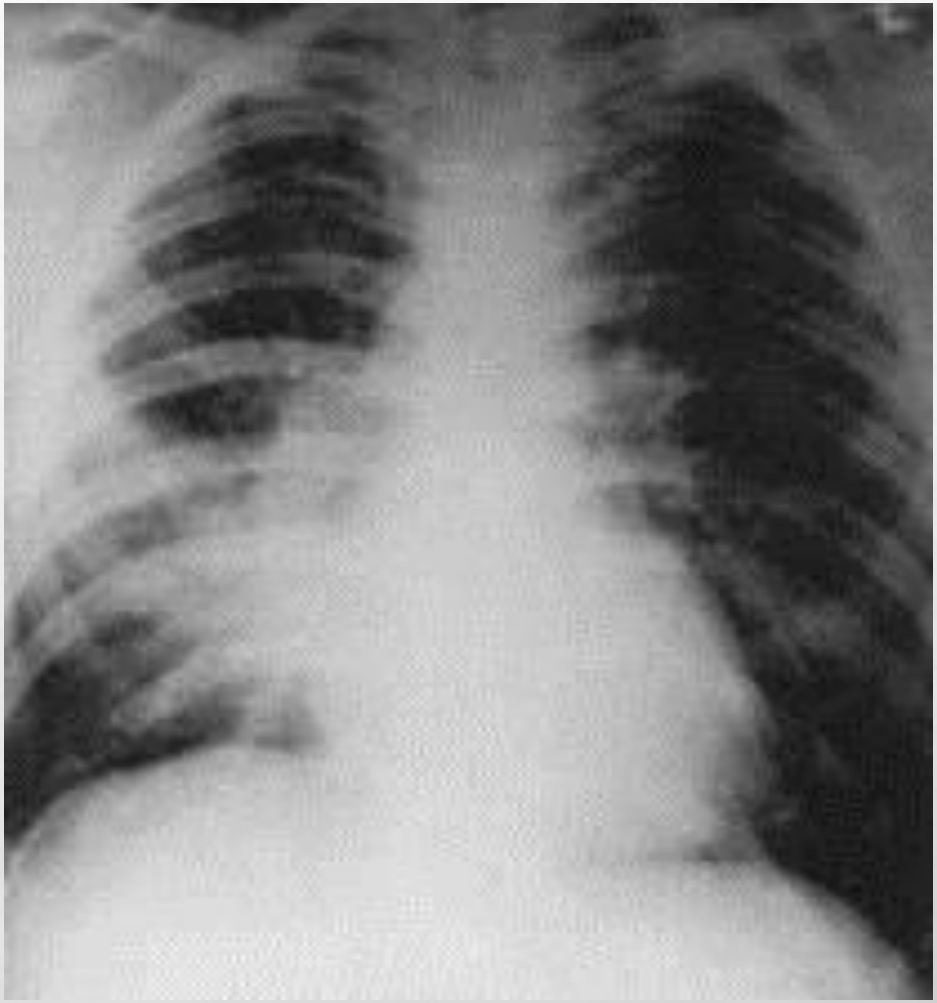

UPPER & MIDDLE LOBAR PNEUMONIA

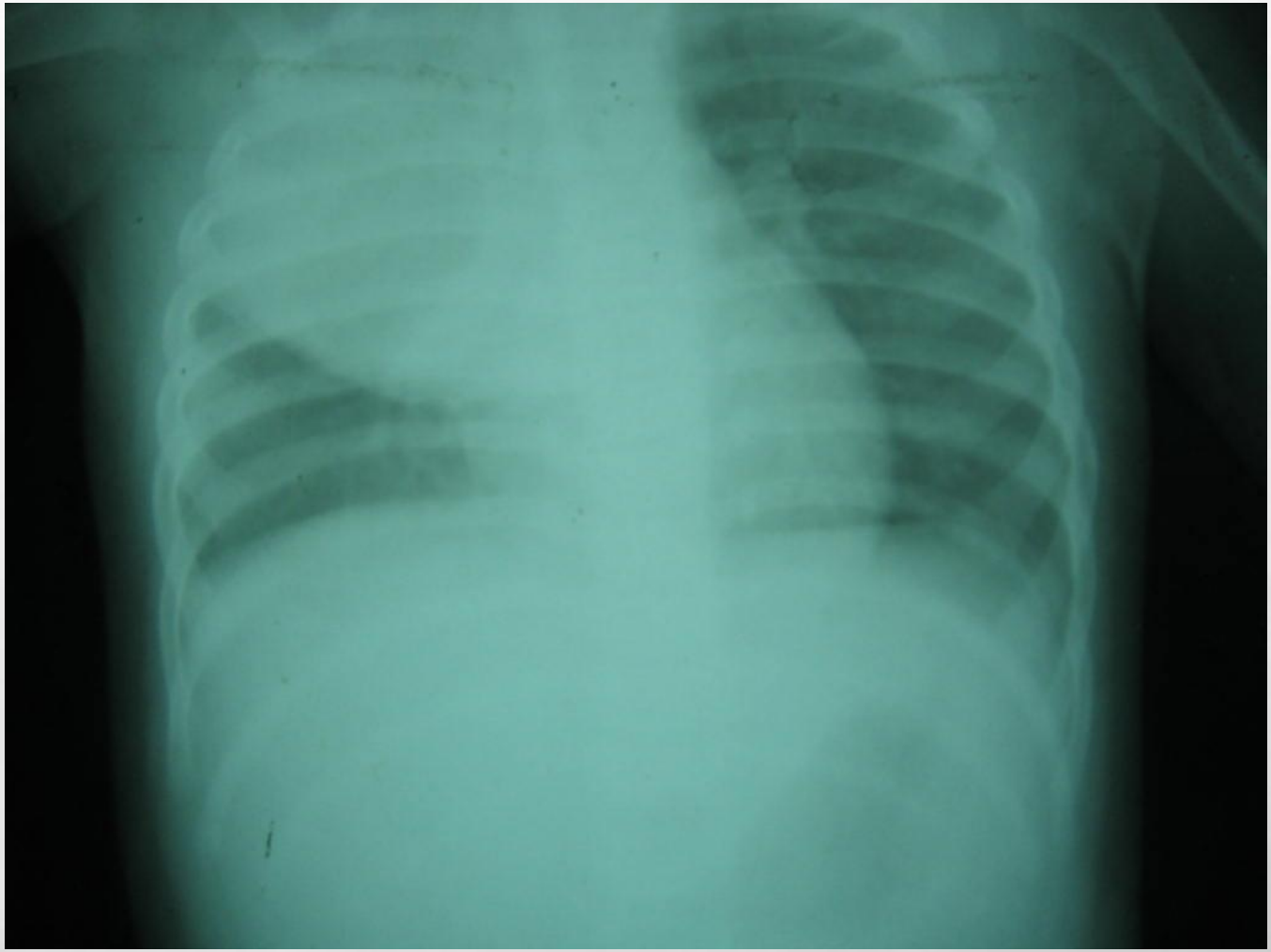

RIGHT HYDROPNEOMOTHORAX

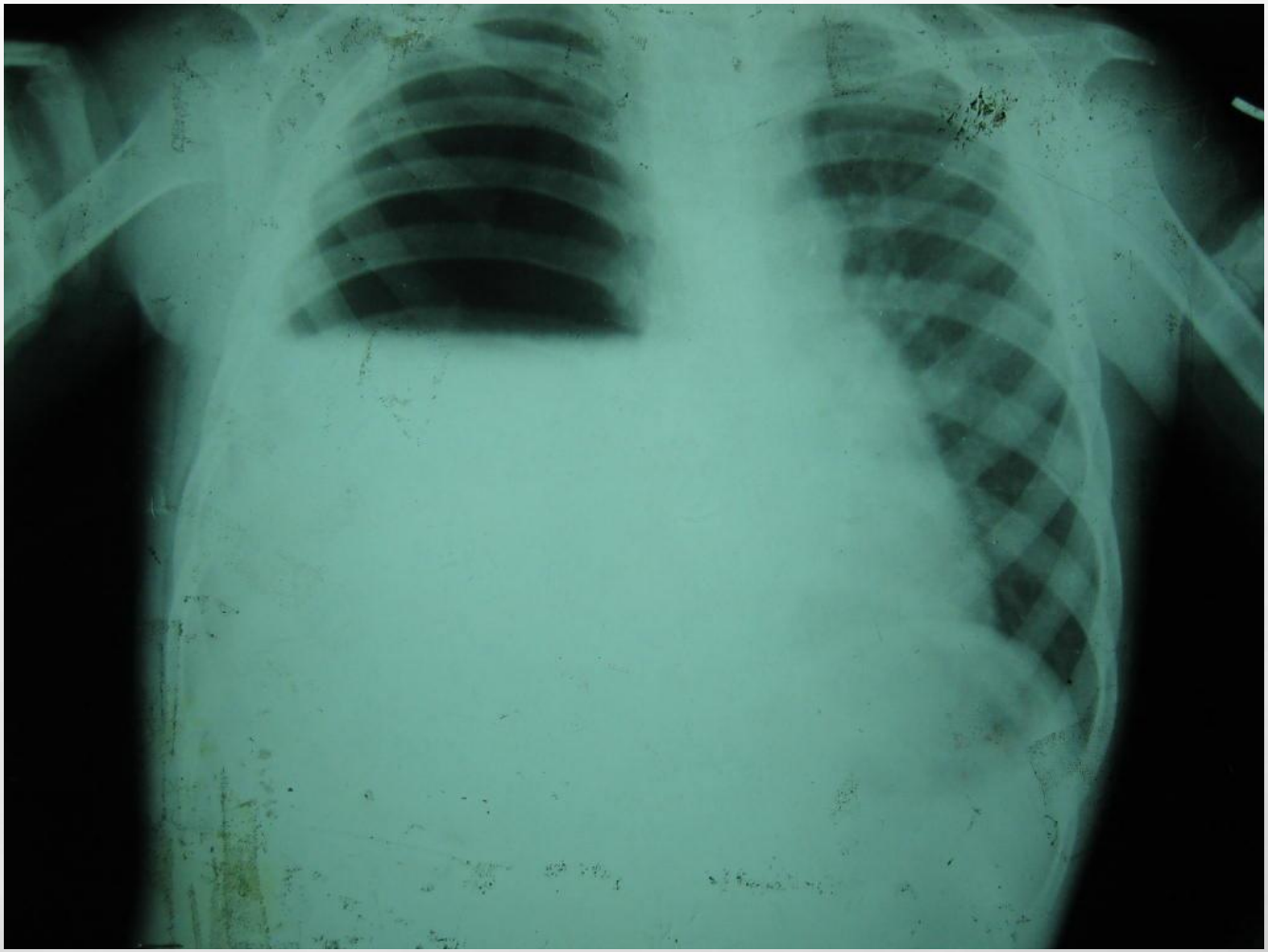

RIGHT HYDROPNEUMOTHORAX

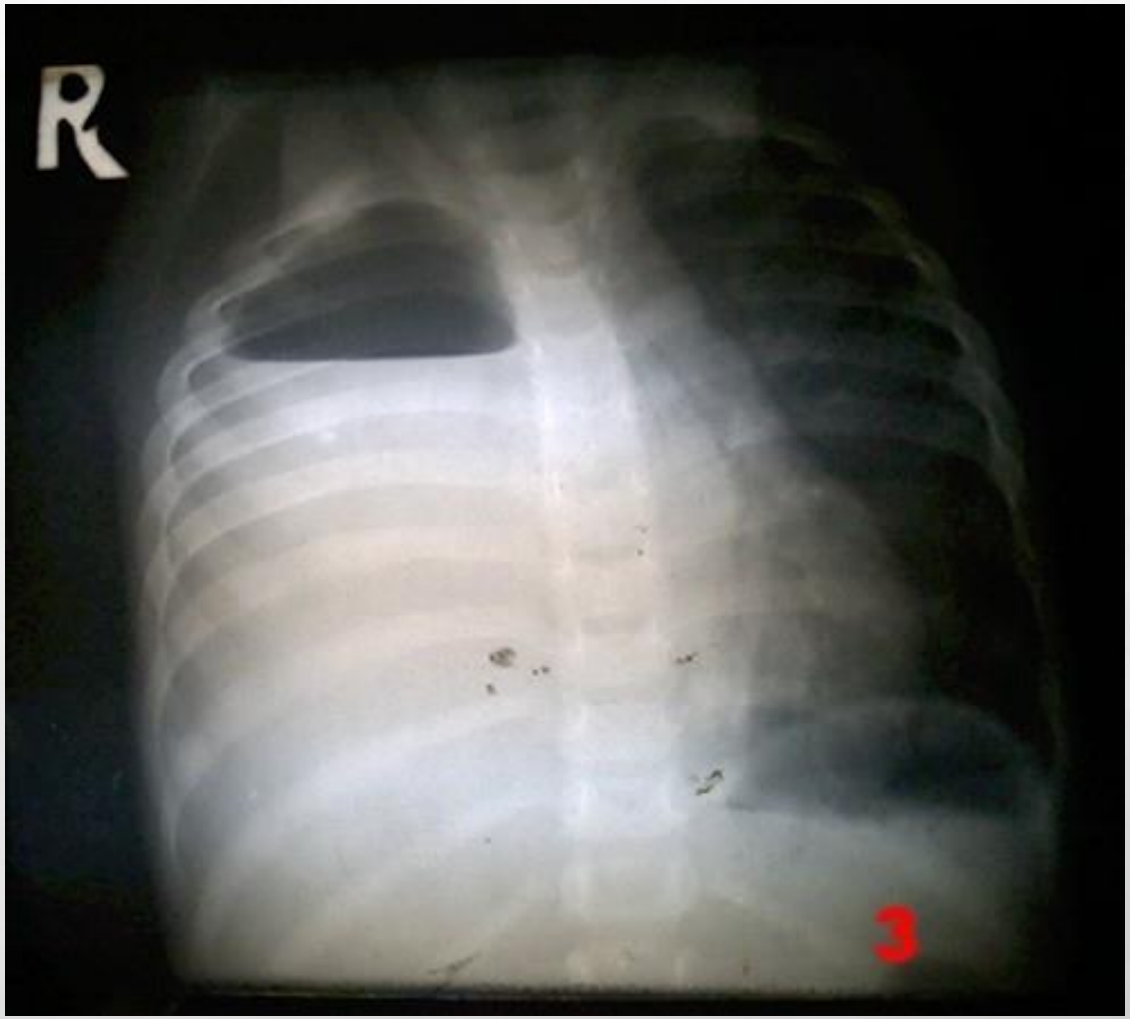

LT. PNEUMOTHORAX

PNEUMOTHORAX

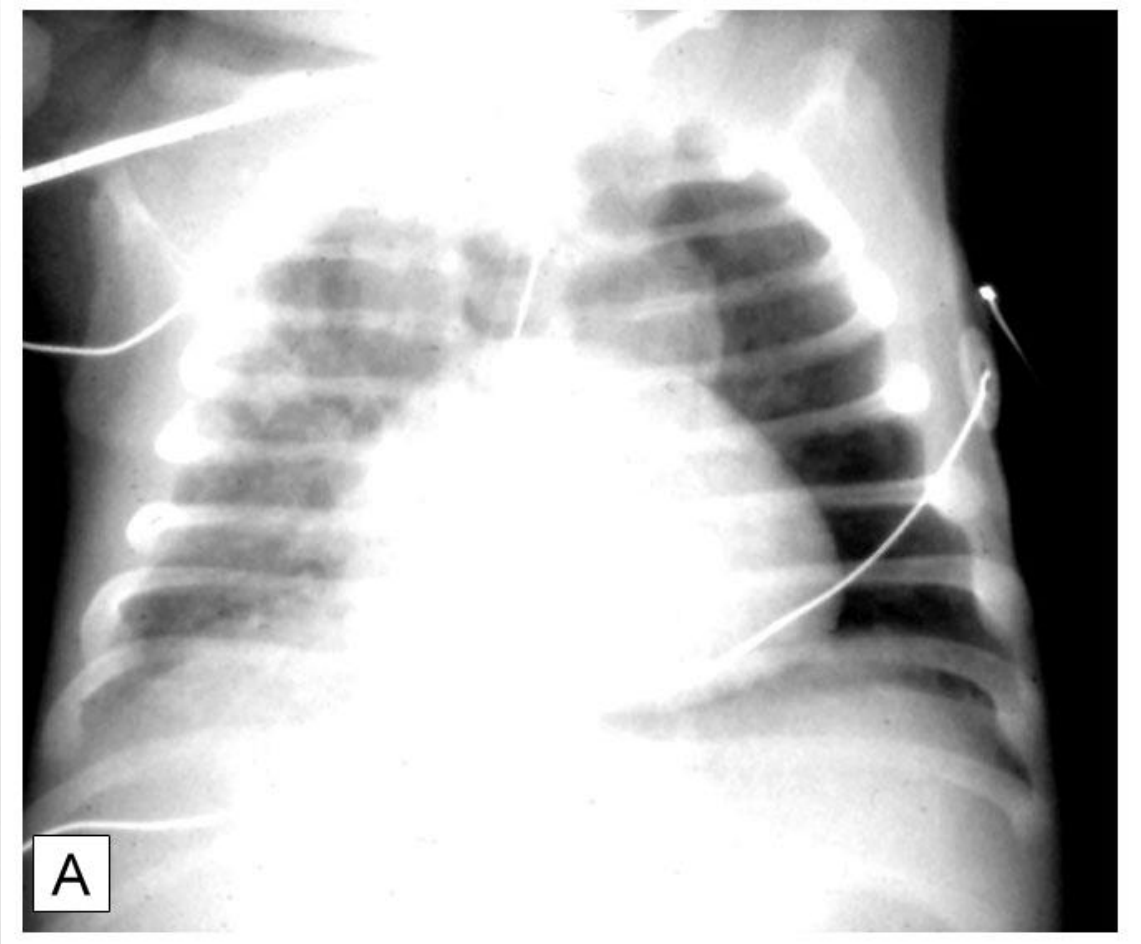

LEFT PLEURAL EFFUSION

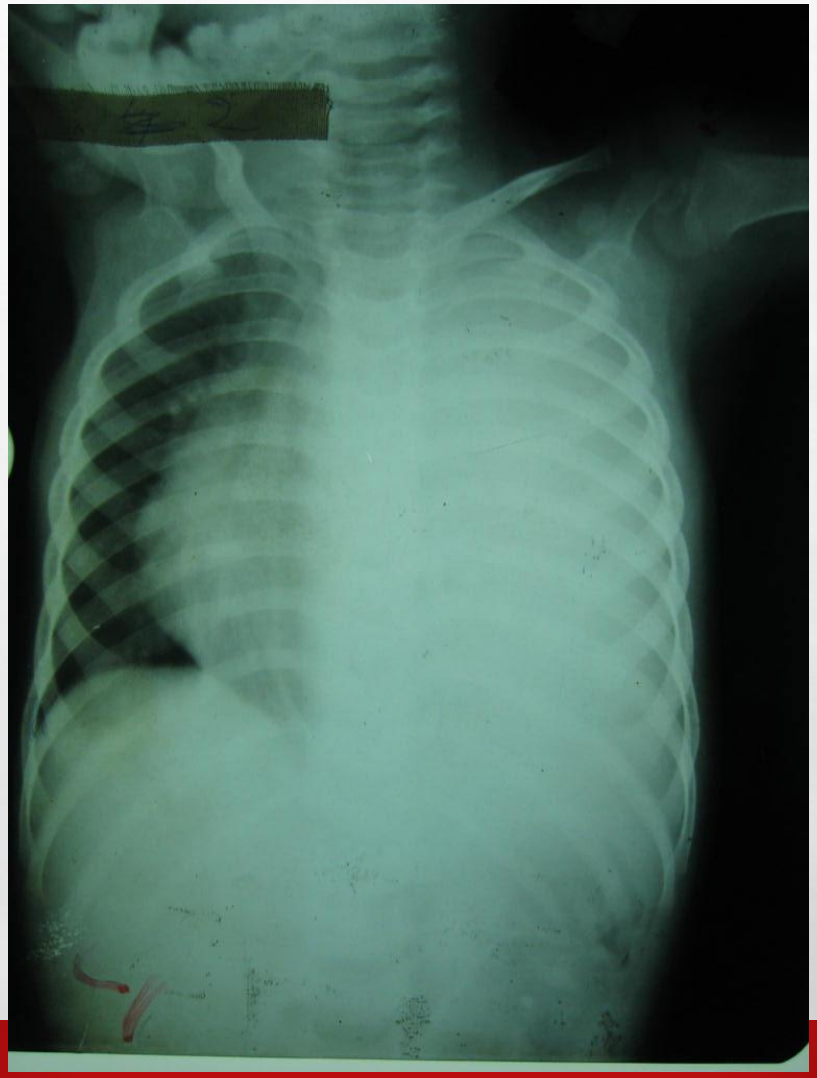

EMPHYSEMA

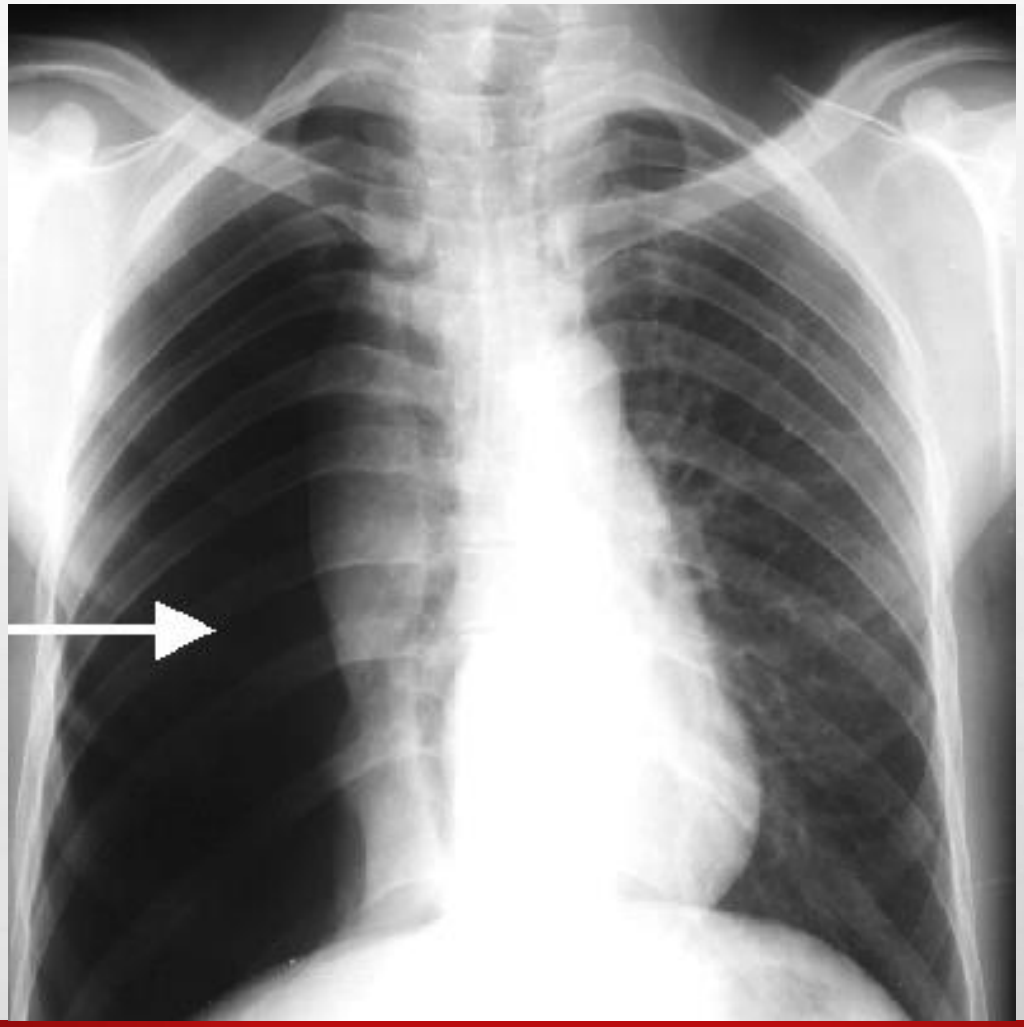

LEFT DIAPHRAGMATIC HERNIA

RIGHT DIAPHRAGMATIC HERNIA

LEFT EMPHYSEMA

MULTIPLE OPACITIES

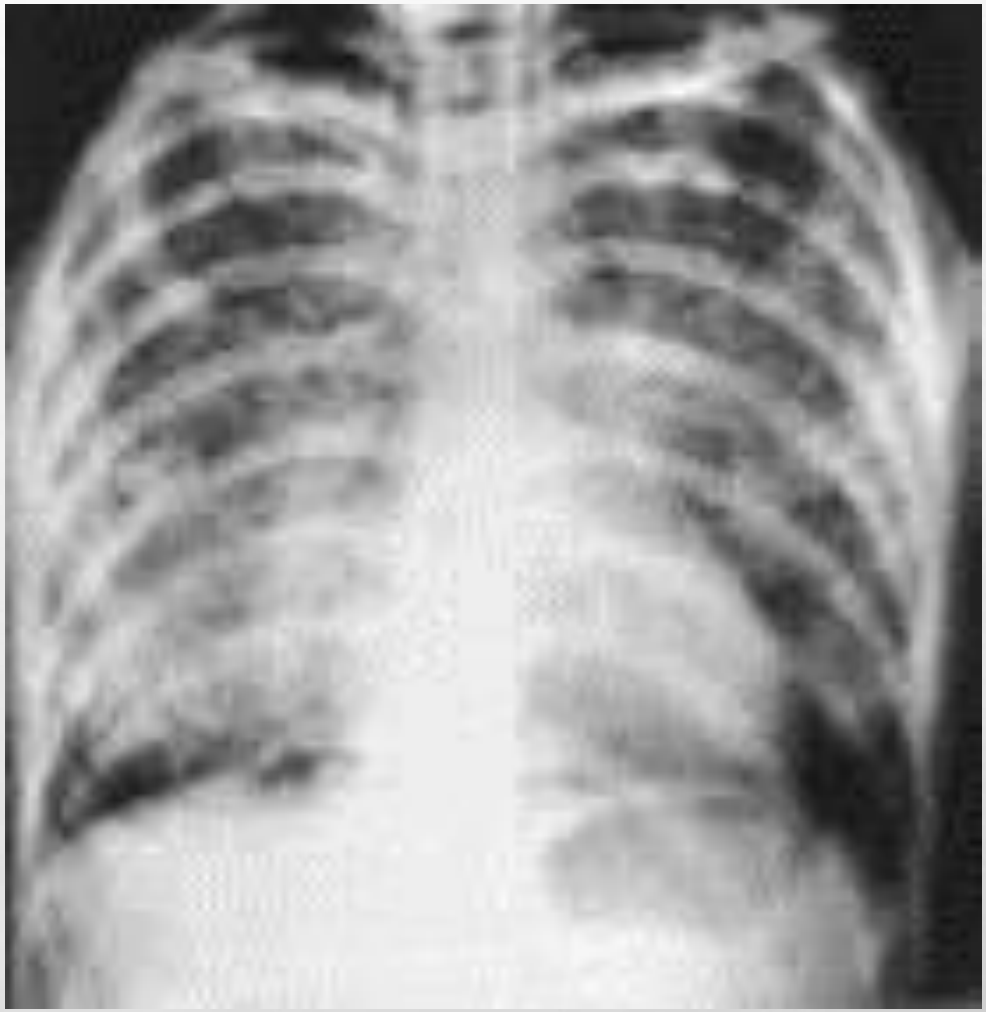

LUNG ABSCESS

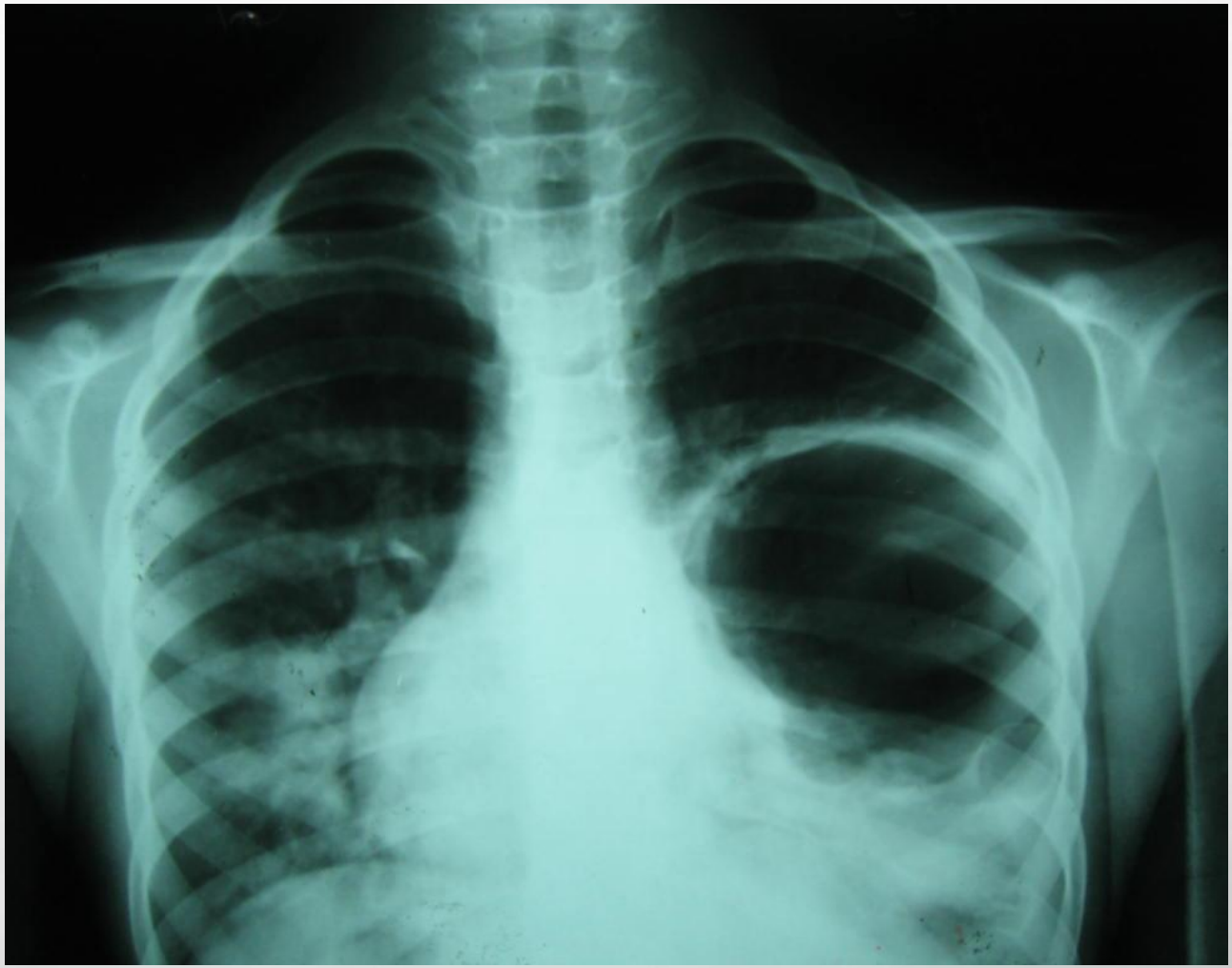

RIGHT OPACITY

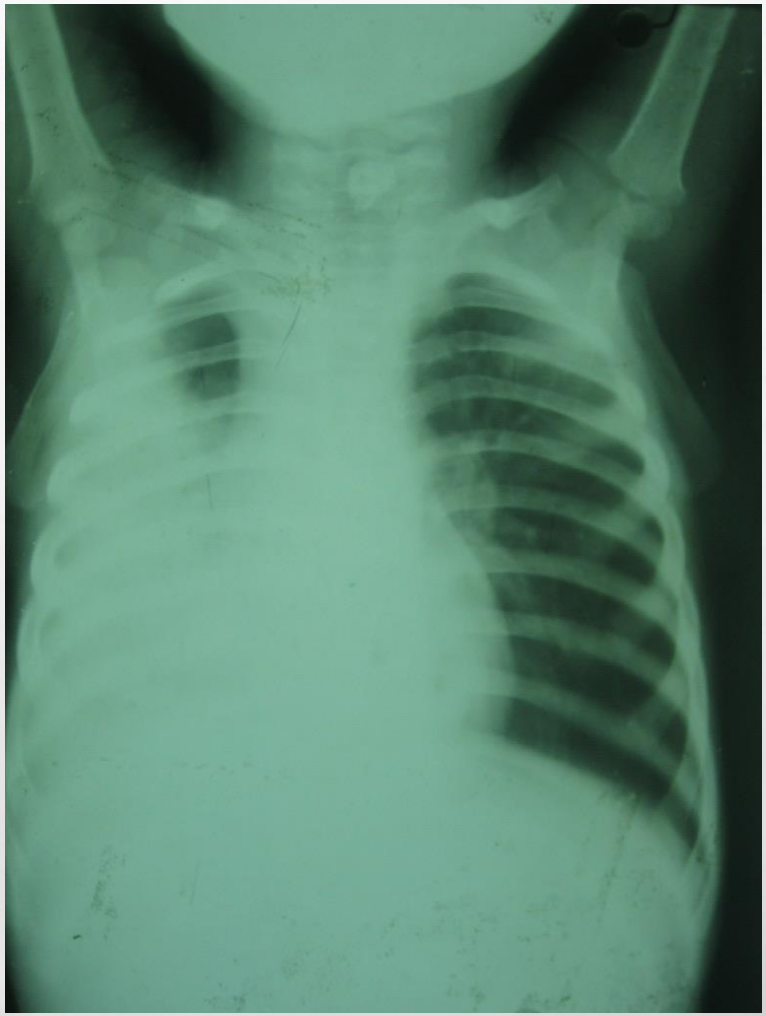

NEONATAL RDS

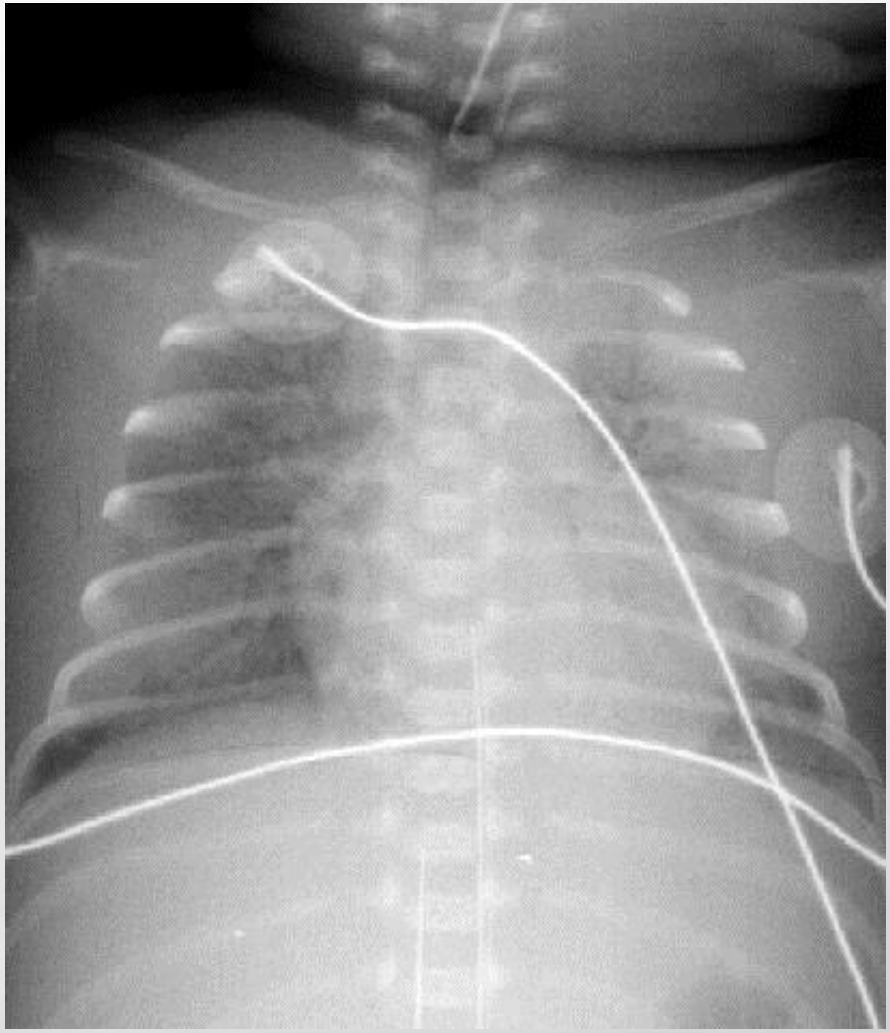

NEONATAL RDS

RDS

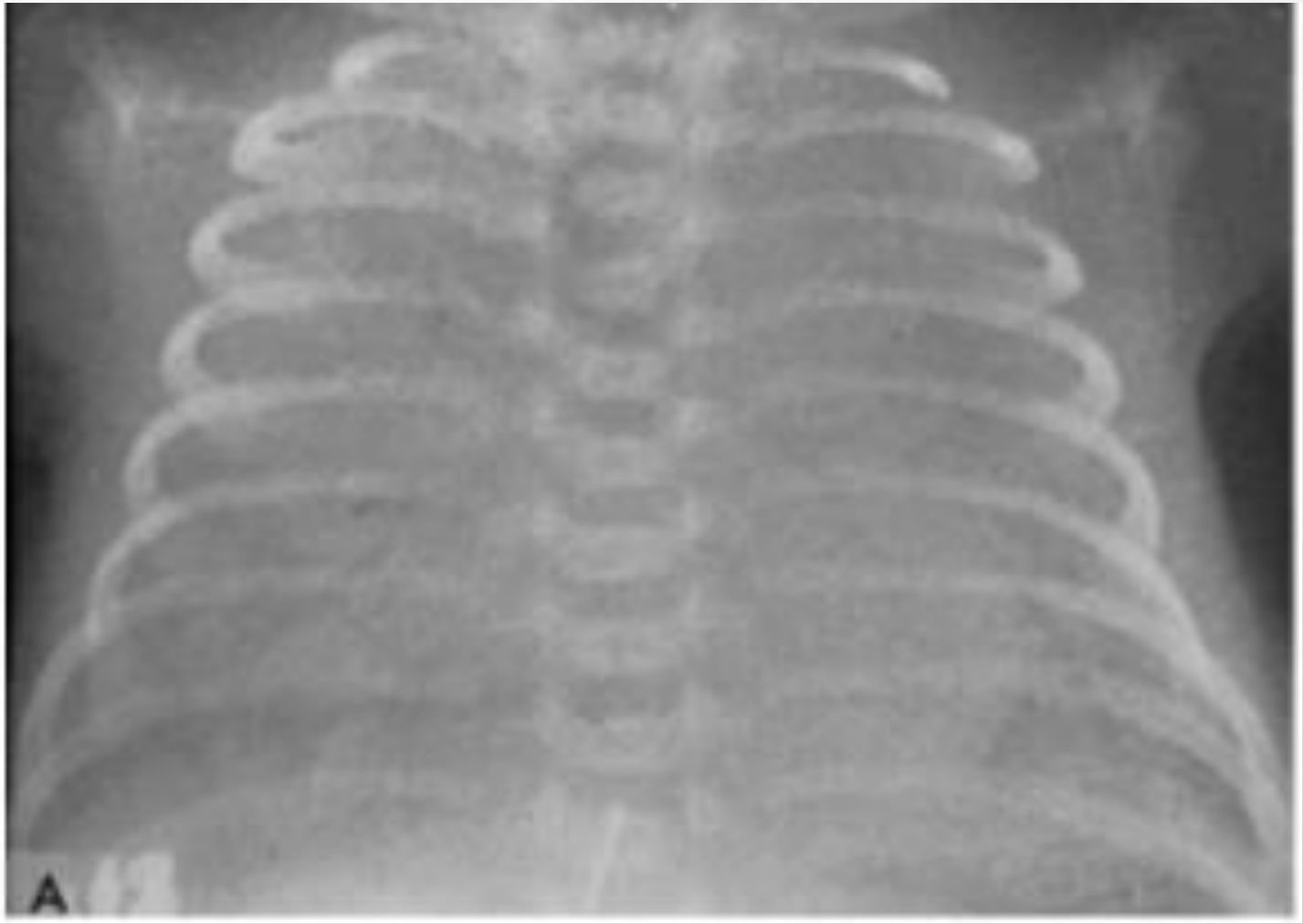

NEONATAL RDS →

MECONIUM ASPIRATION

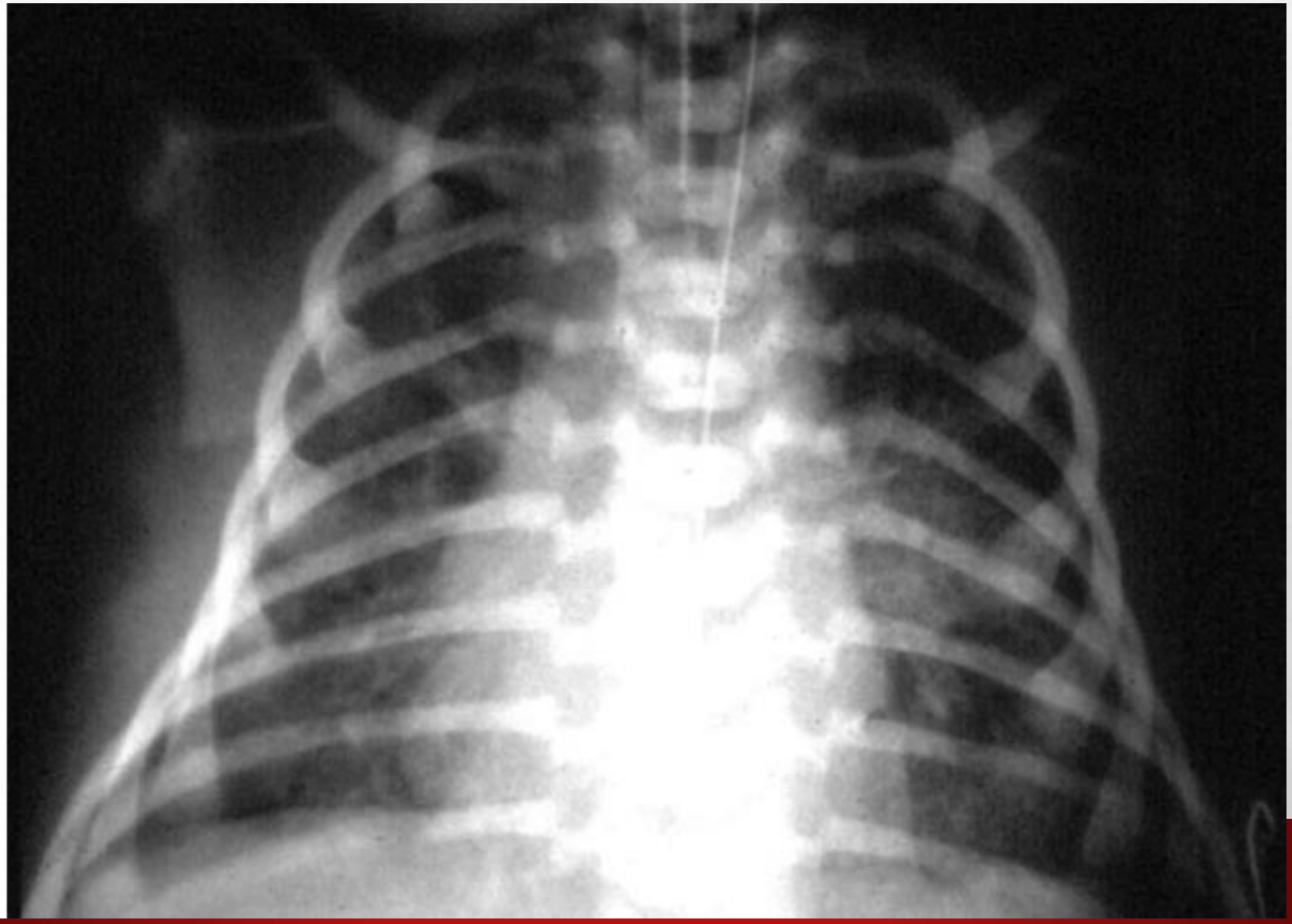

BONE

NORMAL

ACTIVE RICKETS

ACTIVE RICKETS

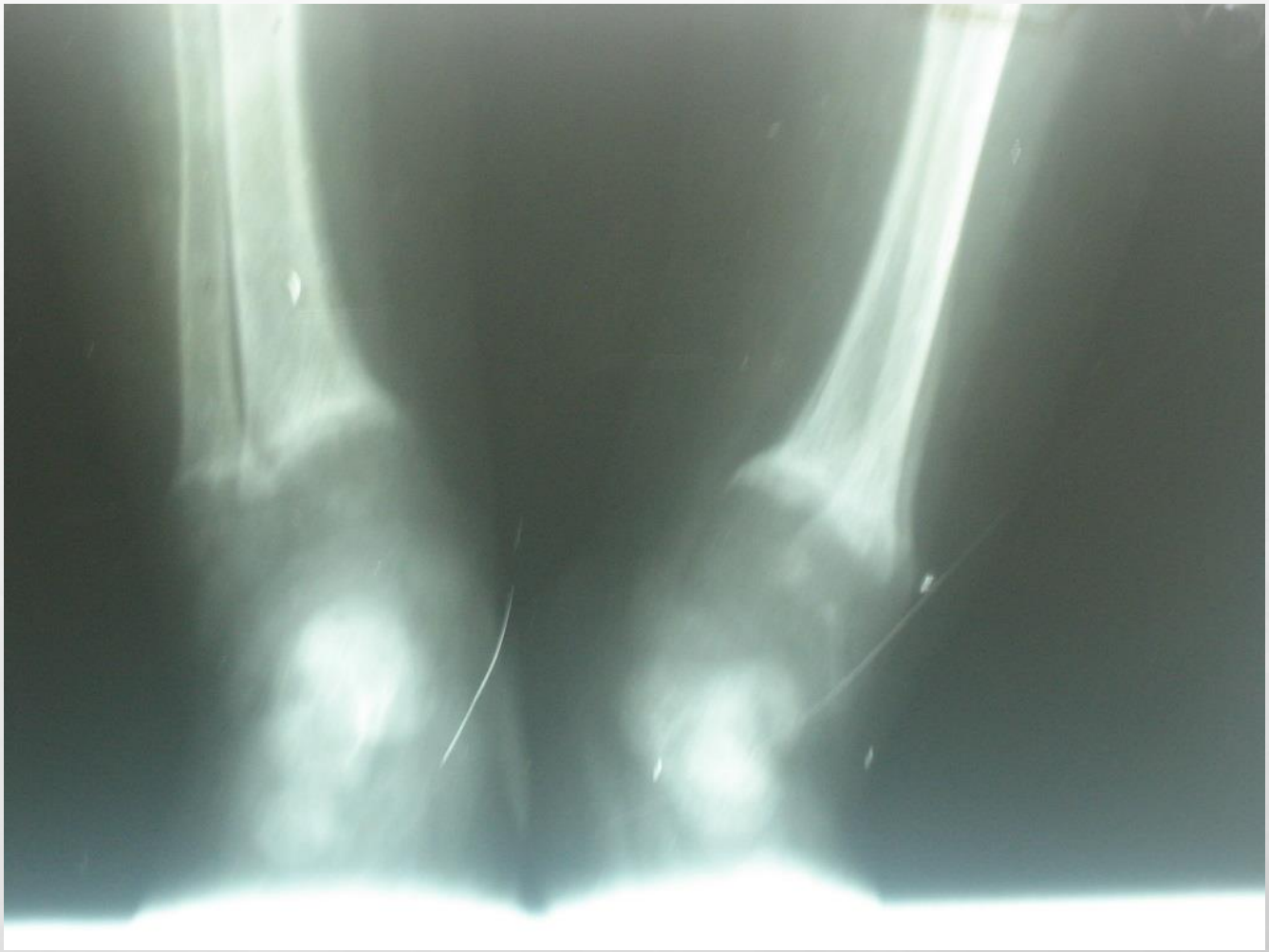

HEALING RICKETS

HEALED RICKETS

RICKETS

RICKETS

ACHONDROPLASIA

OSTEOGENESIS IMPERFECTA

OSTEOGENESIS IMPERFECTA

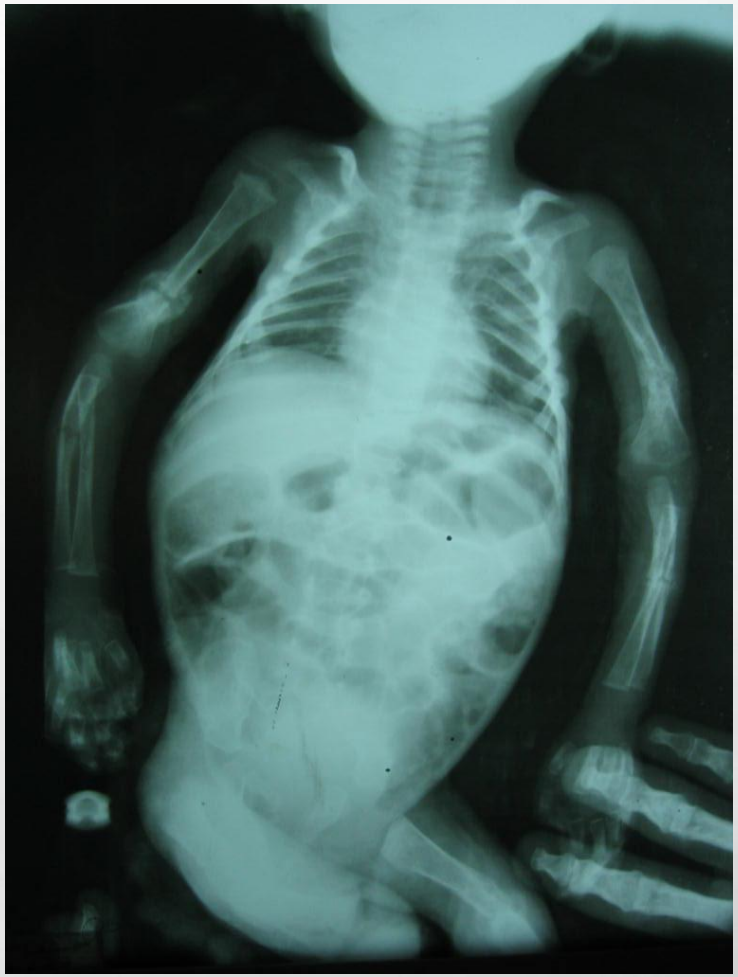

OSTEOMYELITIS

RHEUMATOID ARTHRITIS

RHEUMATOID ARTHRITIS

DELAYED BONE AGE (5.5 YEARS)

105- SICKLE-CELL ANEMIA WITH PARATYPHOID OSTEOMYELITIS

SICKLE CELL ANEMIA

SICKLE CELL ANEMIA

FRACTURE HUMMERS

NEONATAL OSTEOMYELITIS

BONE CYST

HISTOCYTOSIS

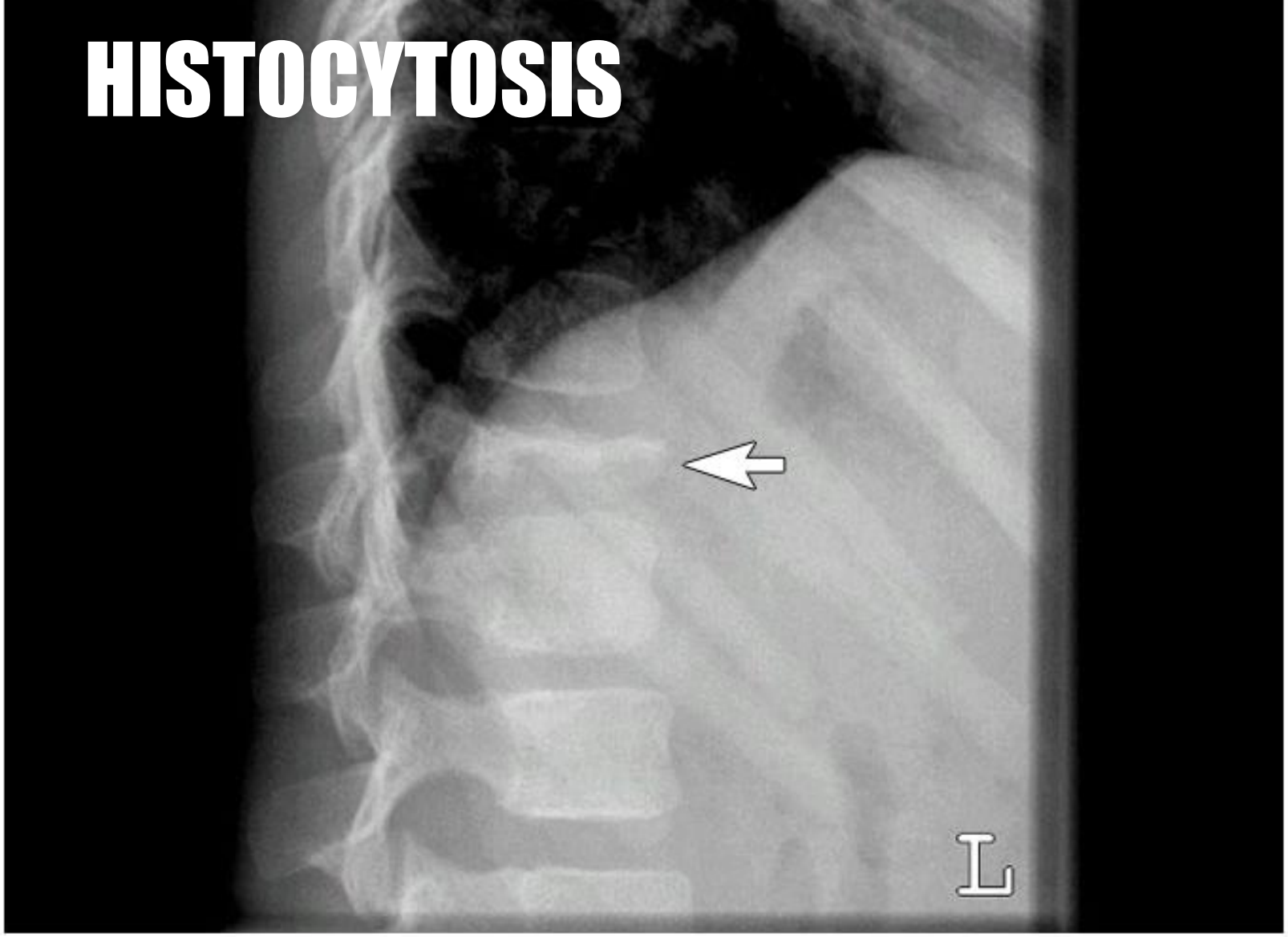

SKELETAL DYSPLASIA

ACHONDROPLASIA

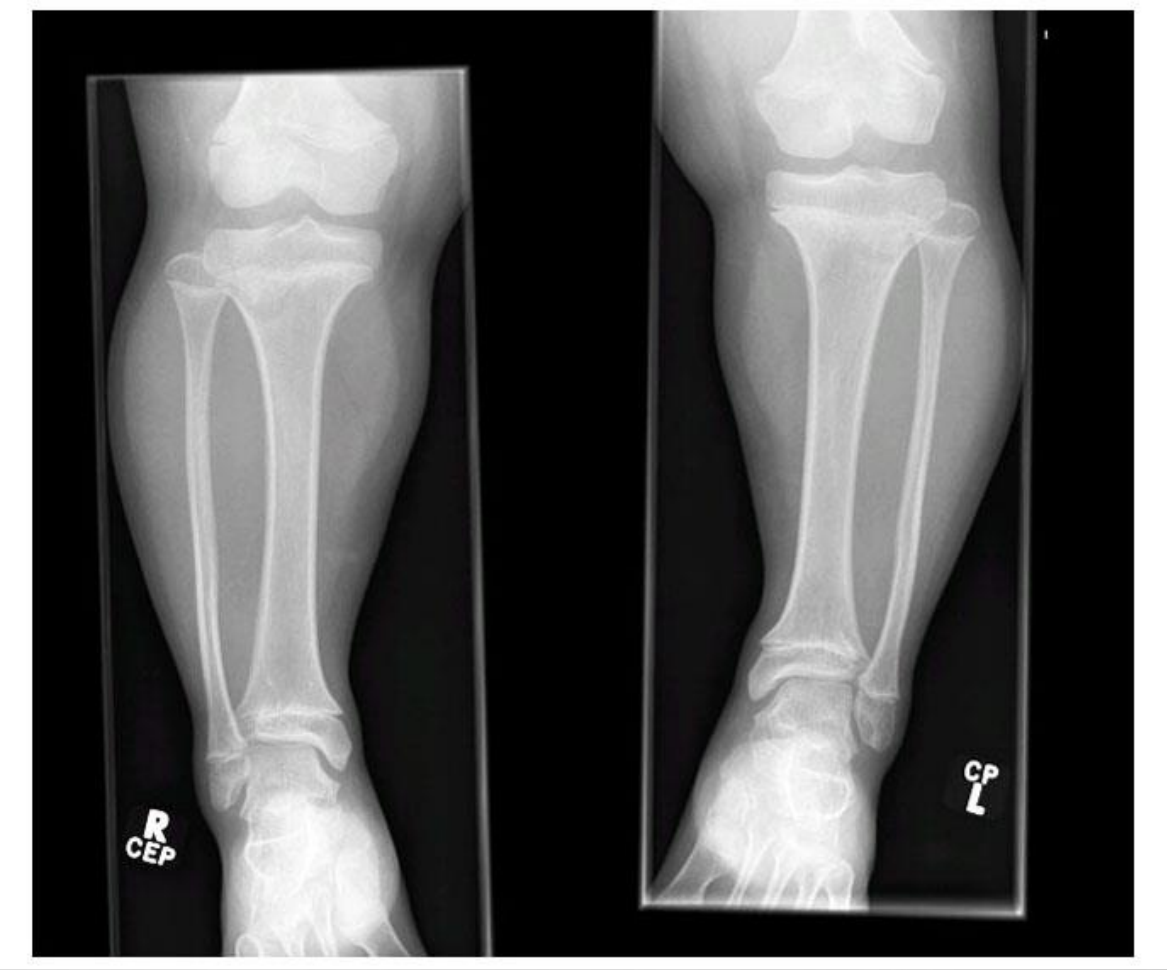

MUCCO POLYSAC-CARIDOSIS

NORMAL BONE

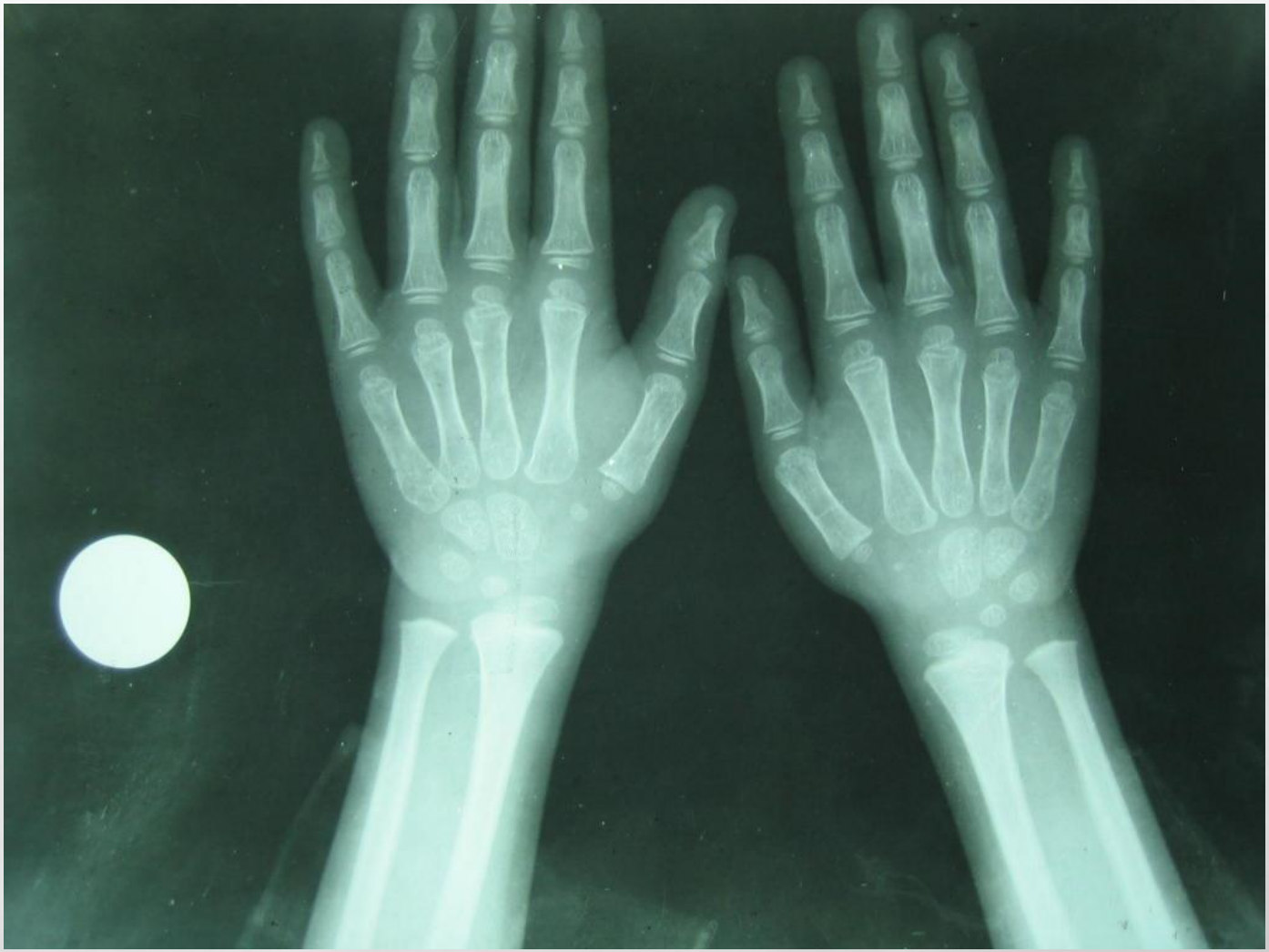

ACTIVE RICKETS

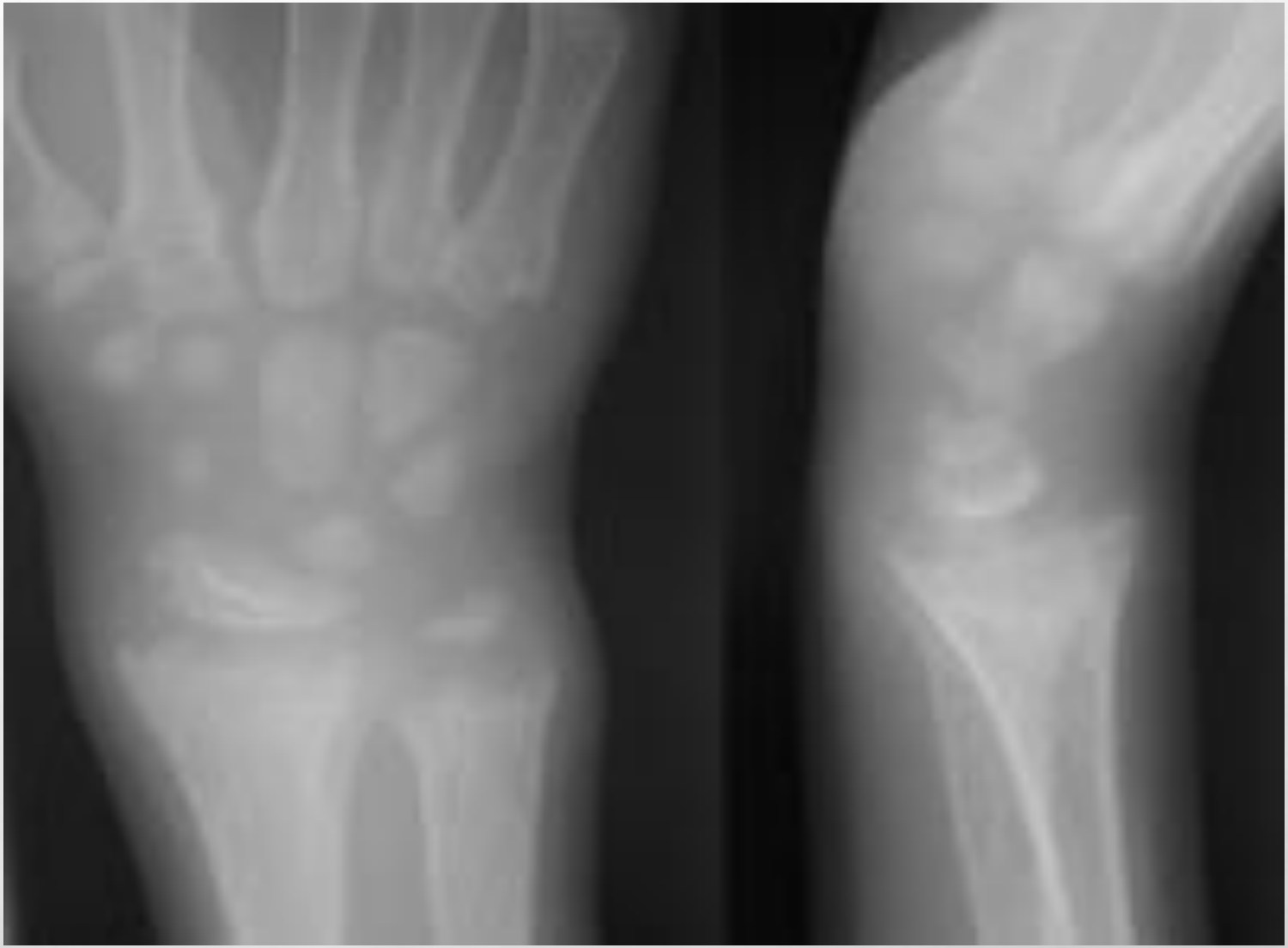

HEALING RICKETS

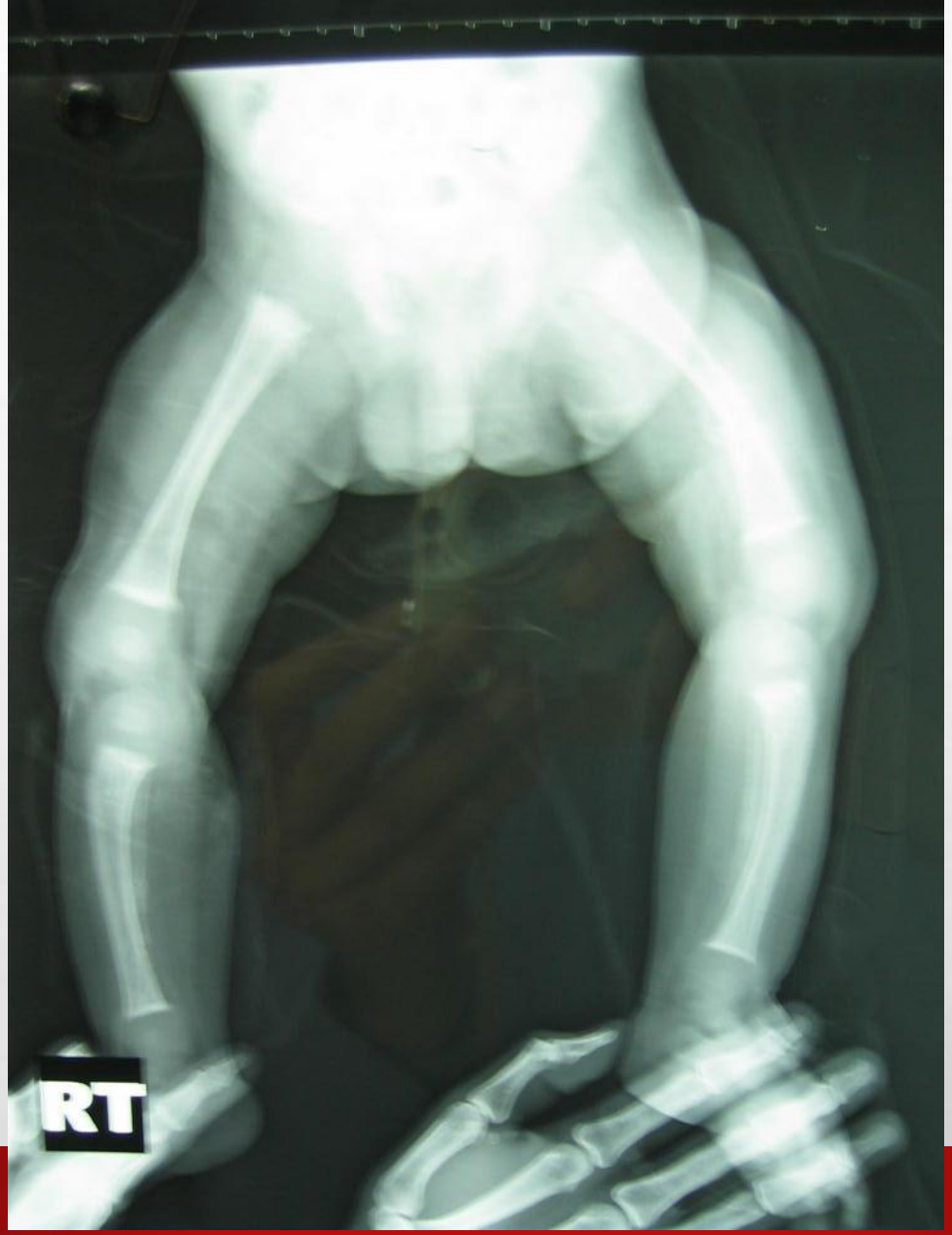
RT

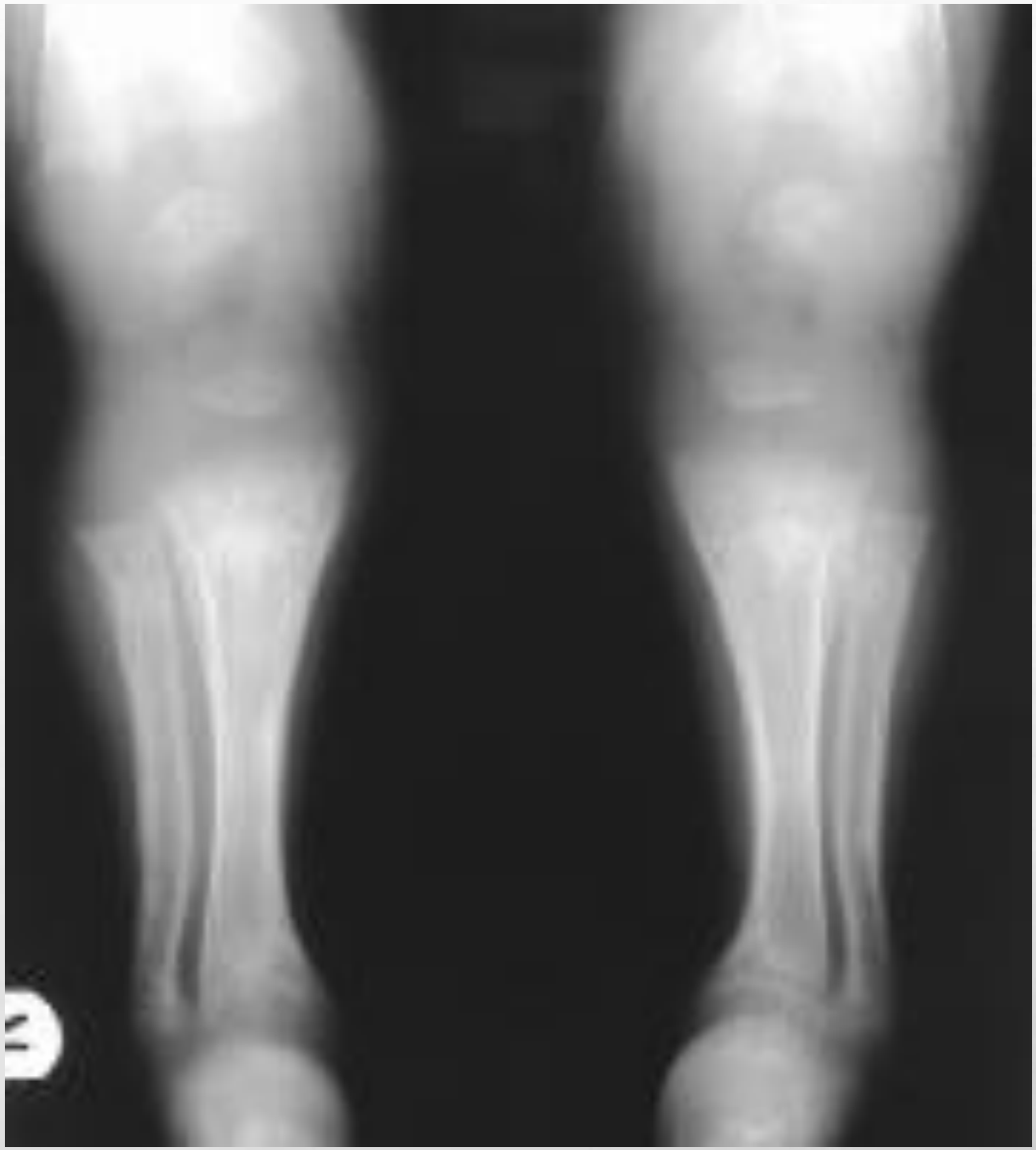

ACHONDROPLASIA

OSTEOGENESIS IMPERFECTA

MULTIPLE BONE FRACTURES

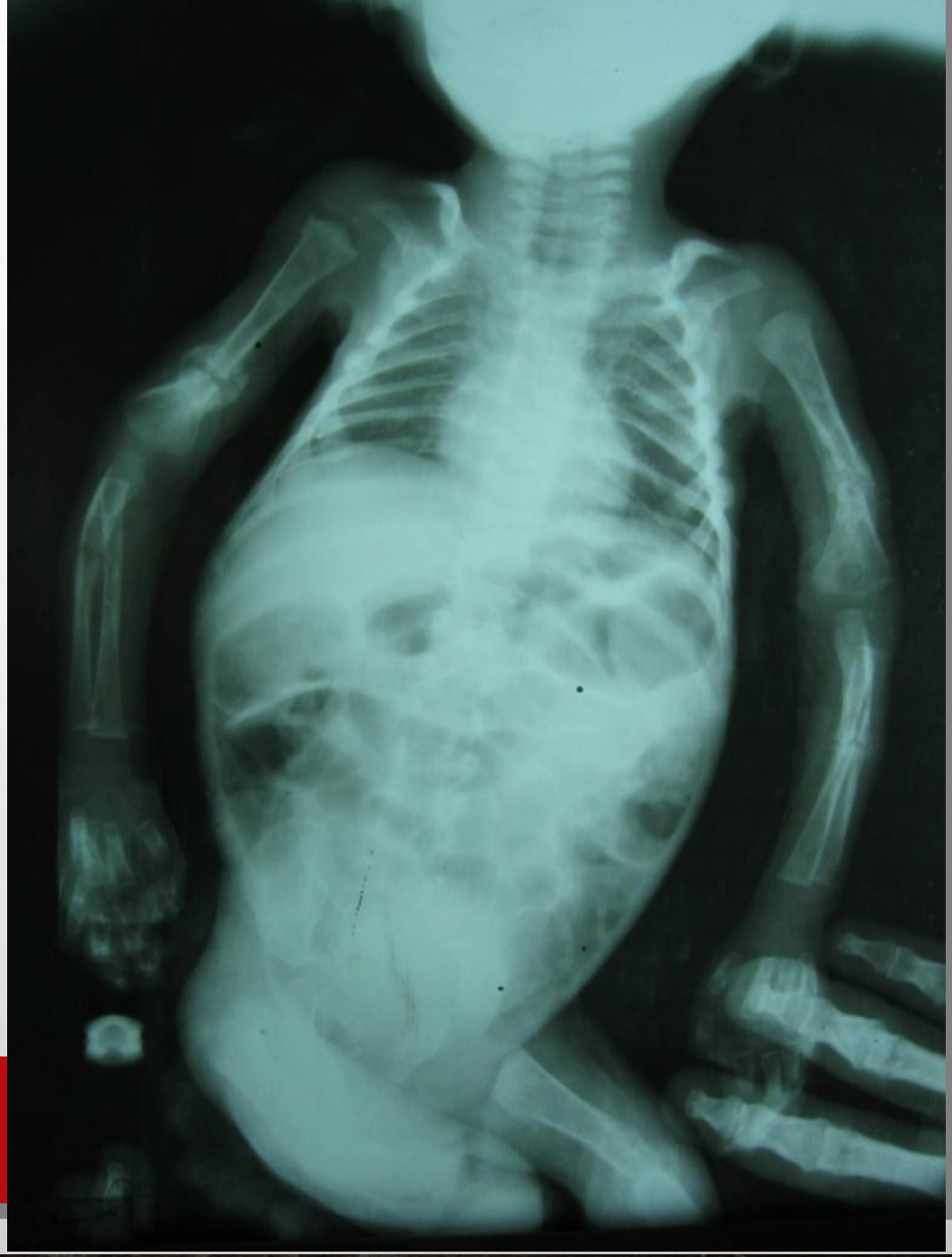

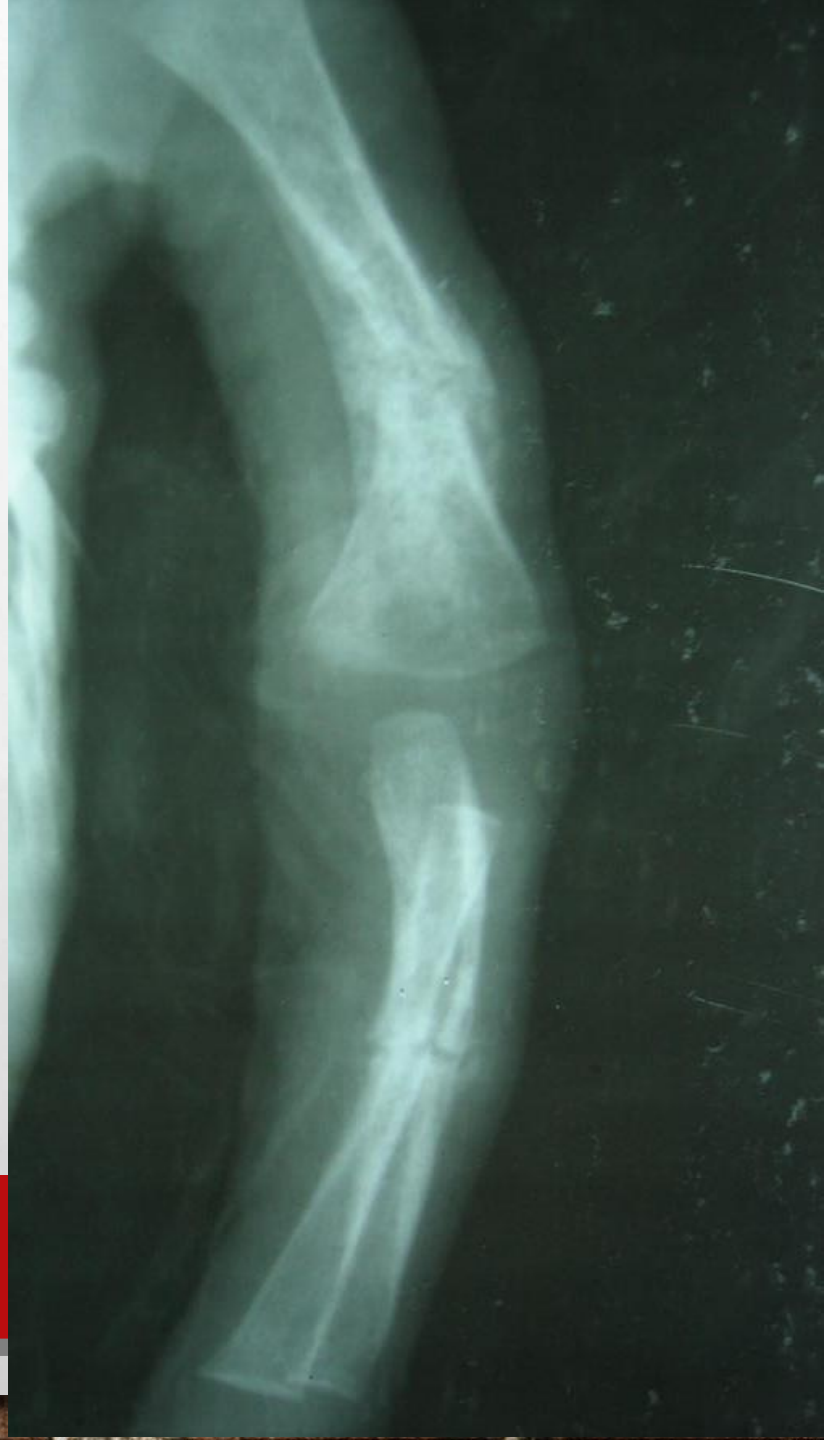

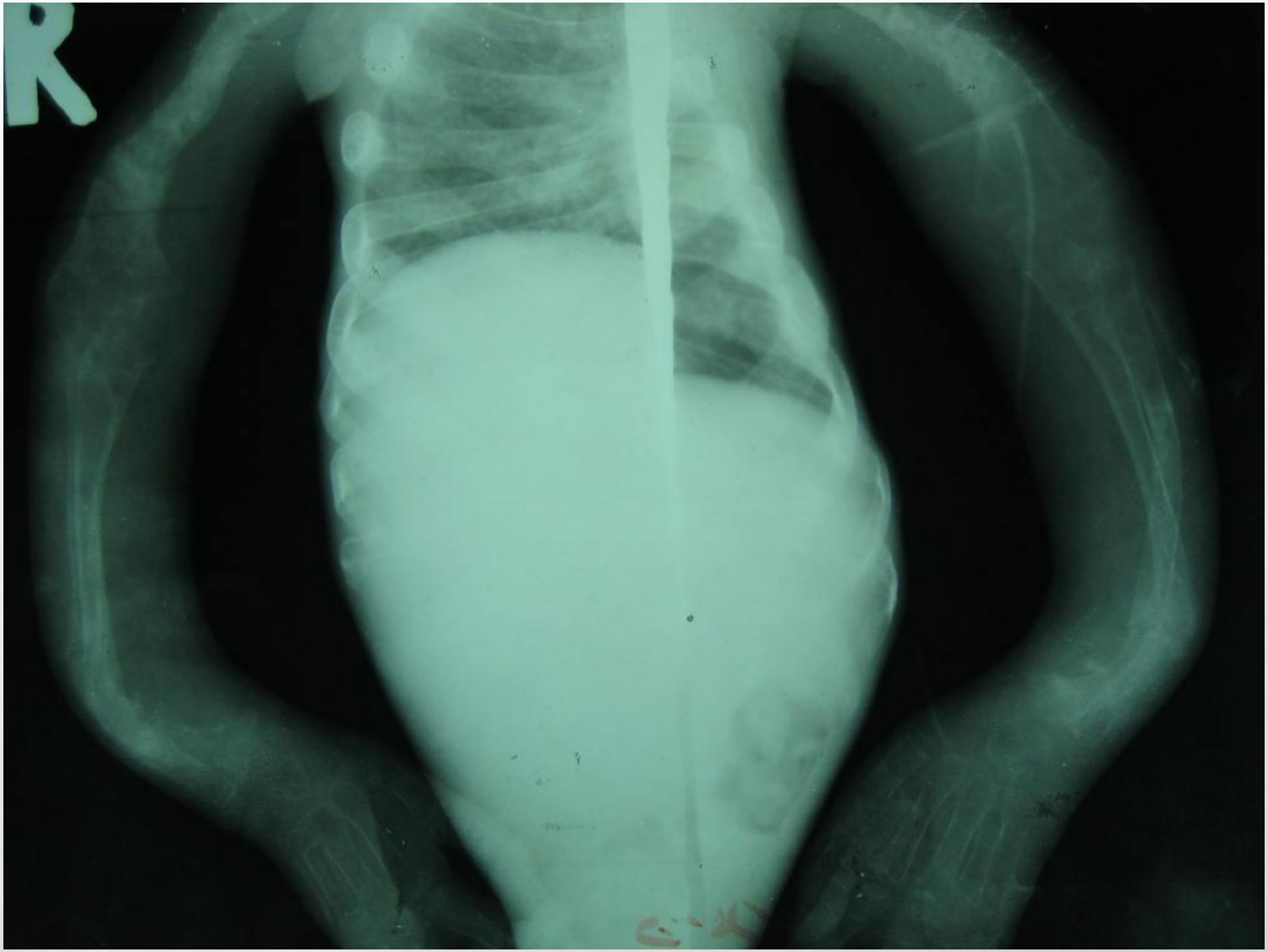
R

RHEUMATOID ARTHRITIS

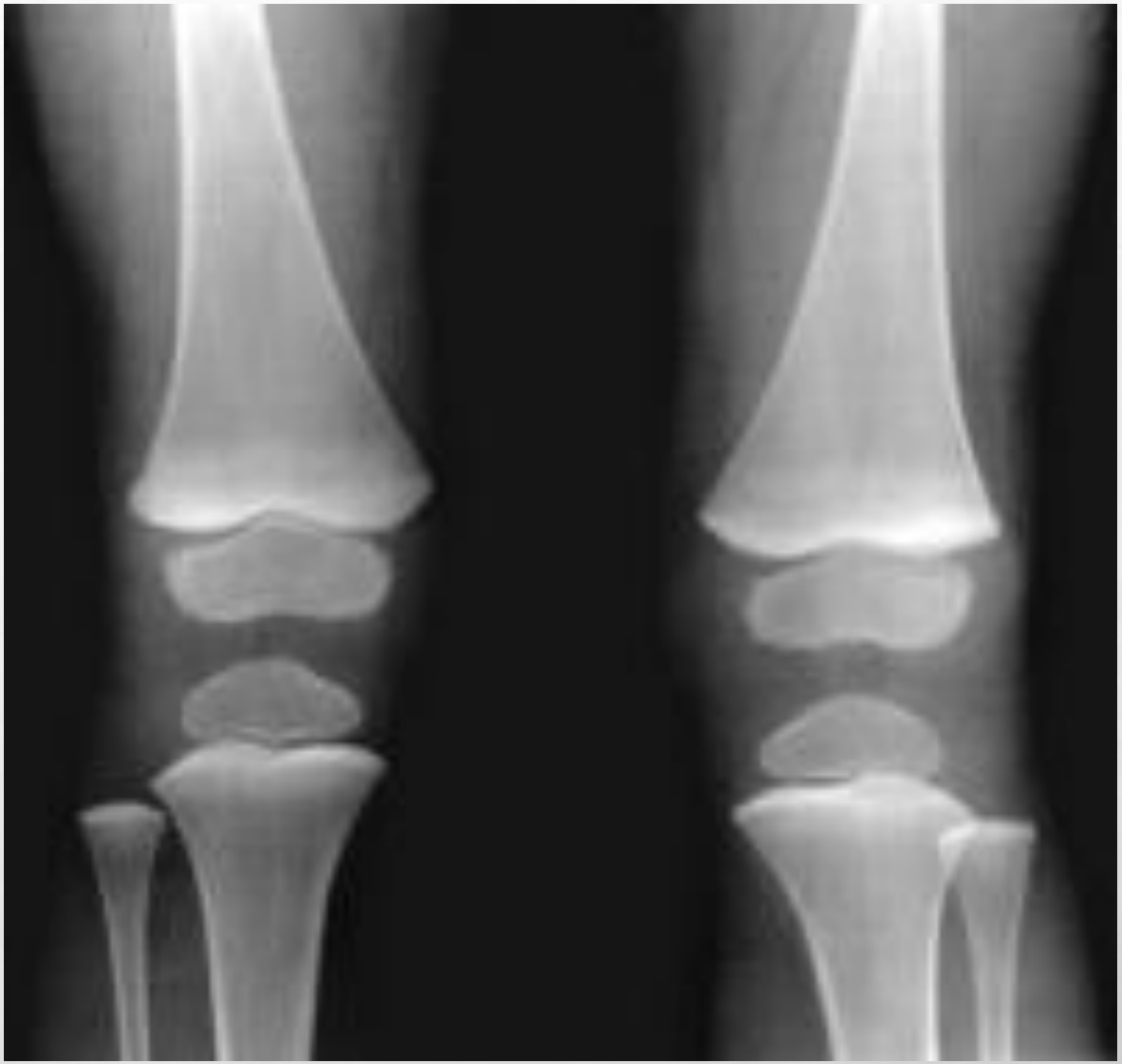

Lead Poisoning

RT

LEAD POISONING →

LEAD POISONING

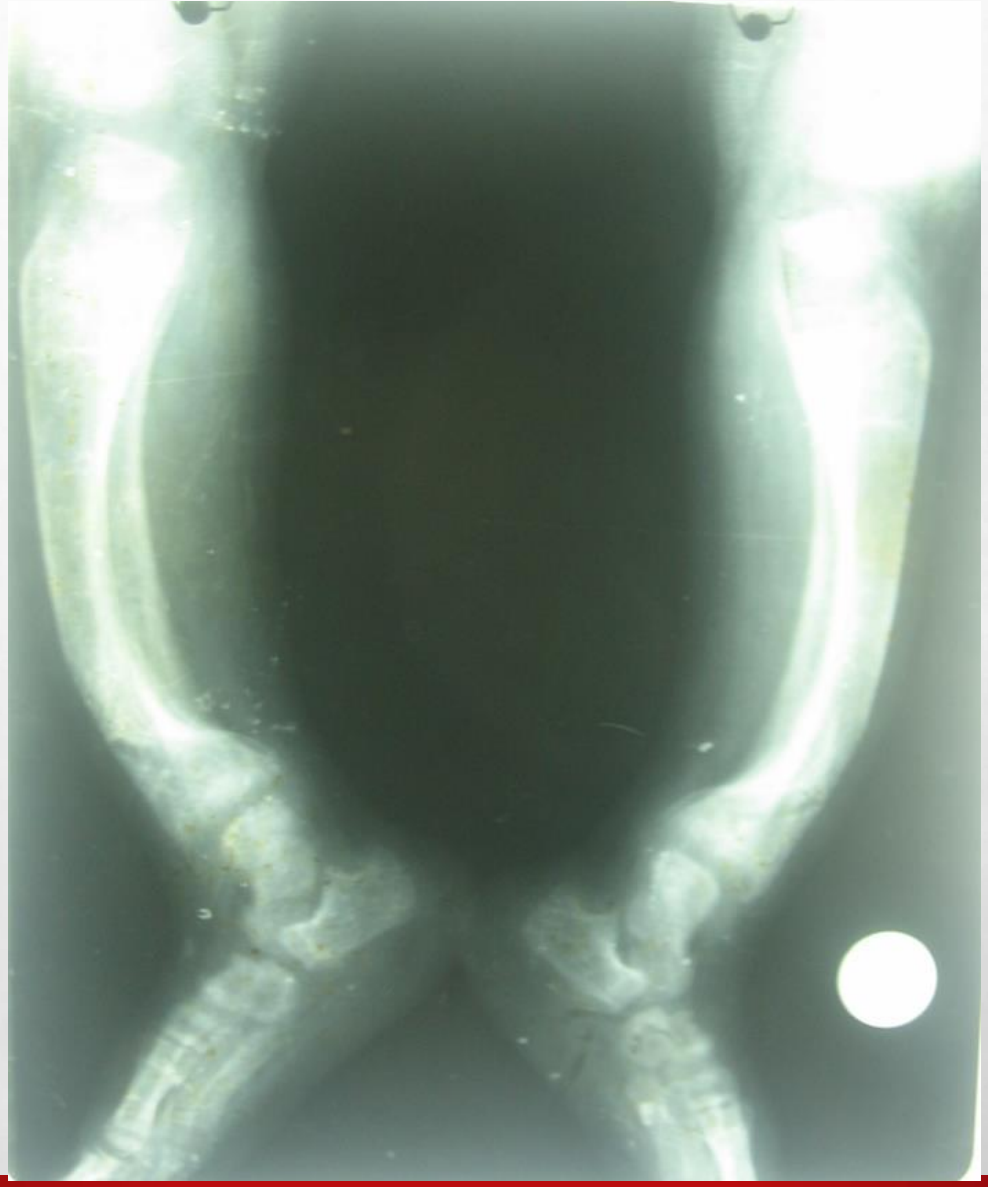

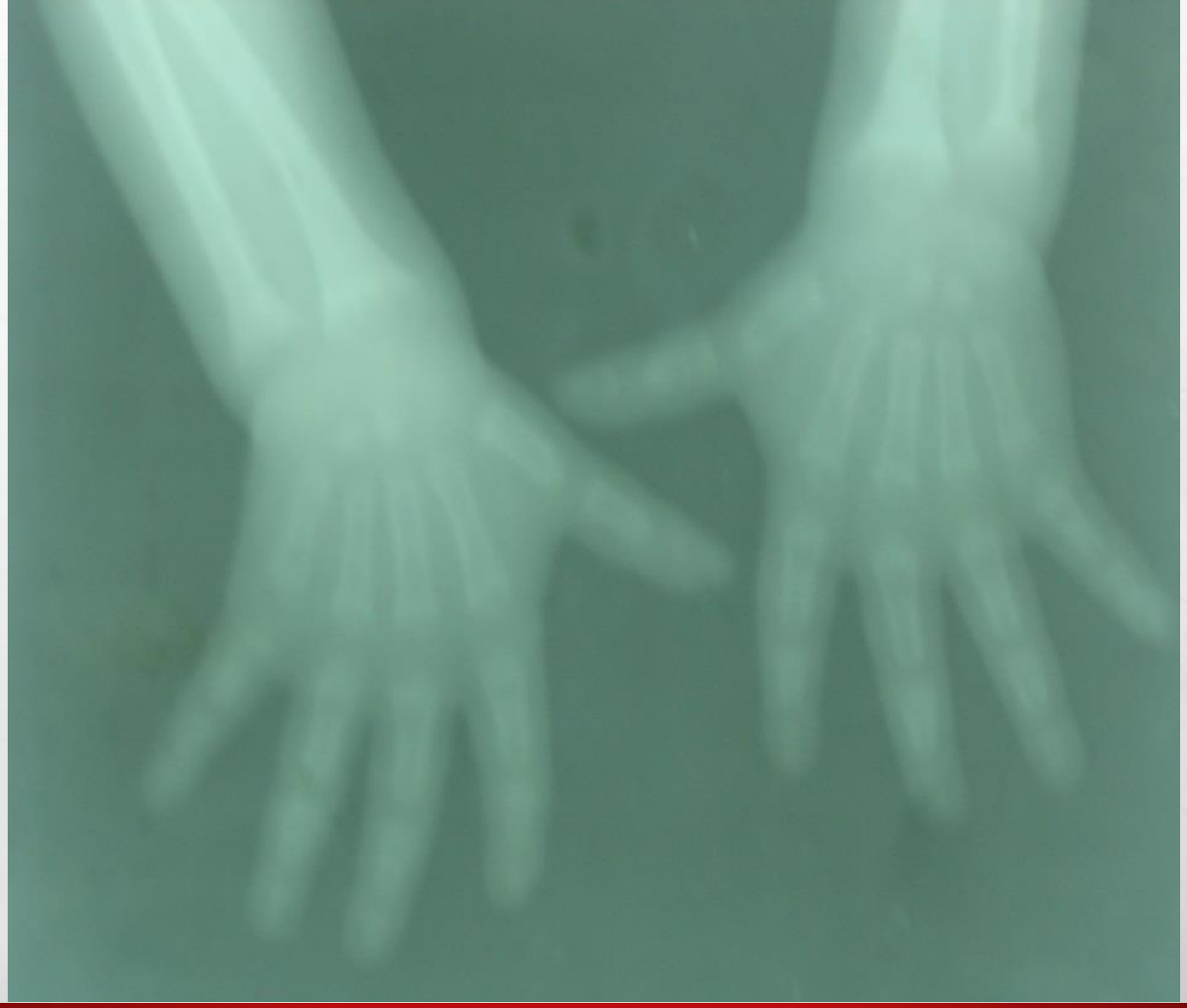

MARBLE BONE DISEASE

HEAD

CRANIOCYNESTOSIS

ENCEPHALOCELE

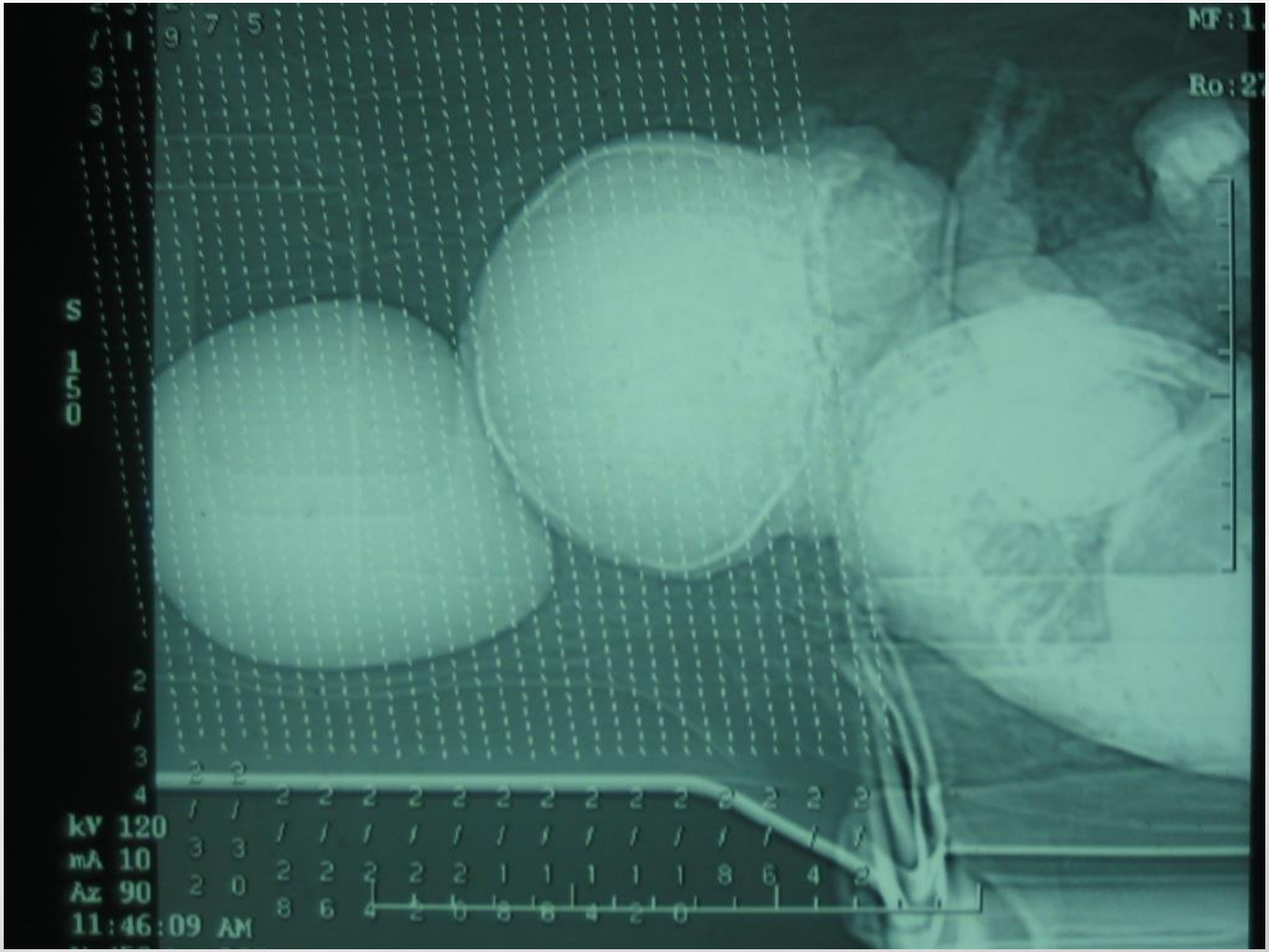

INCREASED INTRA CRANIAL PRESSURE

SILVER BITTEN APPEARANCE

HYDROCEPHALUS

HAIR ON END APPEARANCE HEMOLYTIC ANEMIA

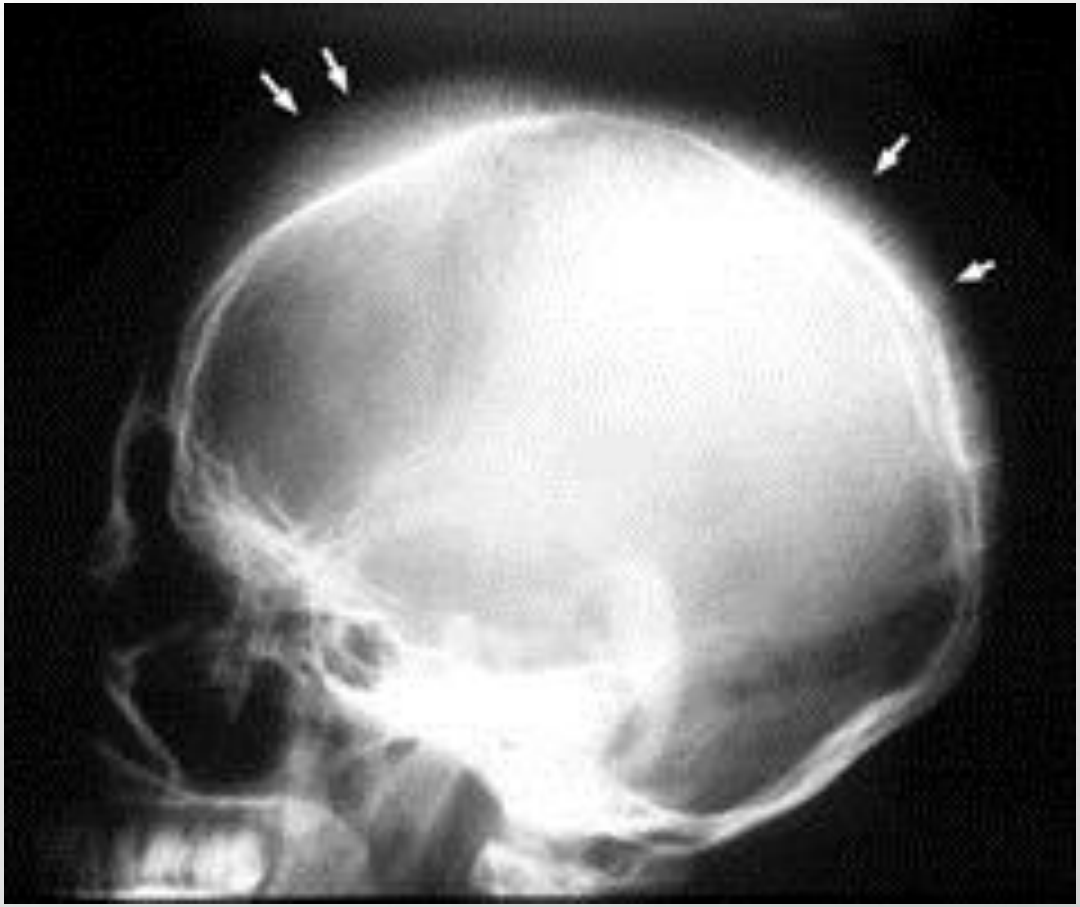

HEMOLYTIC ANEMIA

HEMOLYTIC ANEMIA

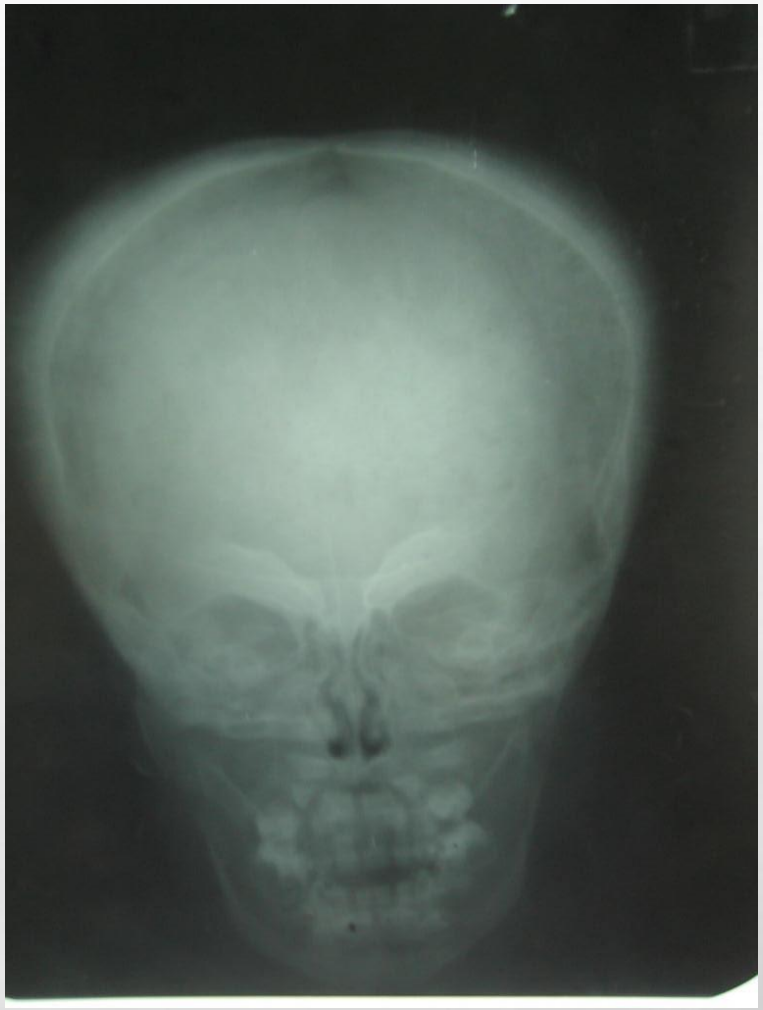

SICKLE CELL ANEMIA

CH. HEMOLYTIC ANEMIA

MICROCEPHALY

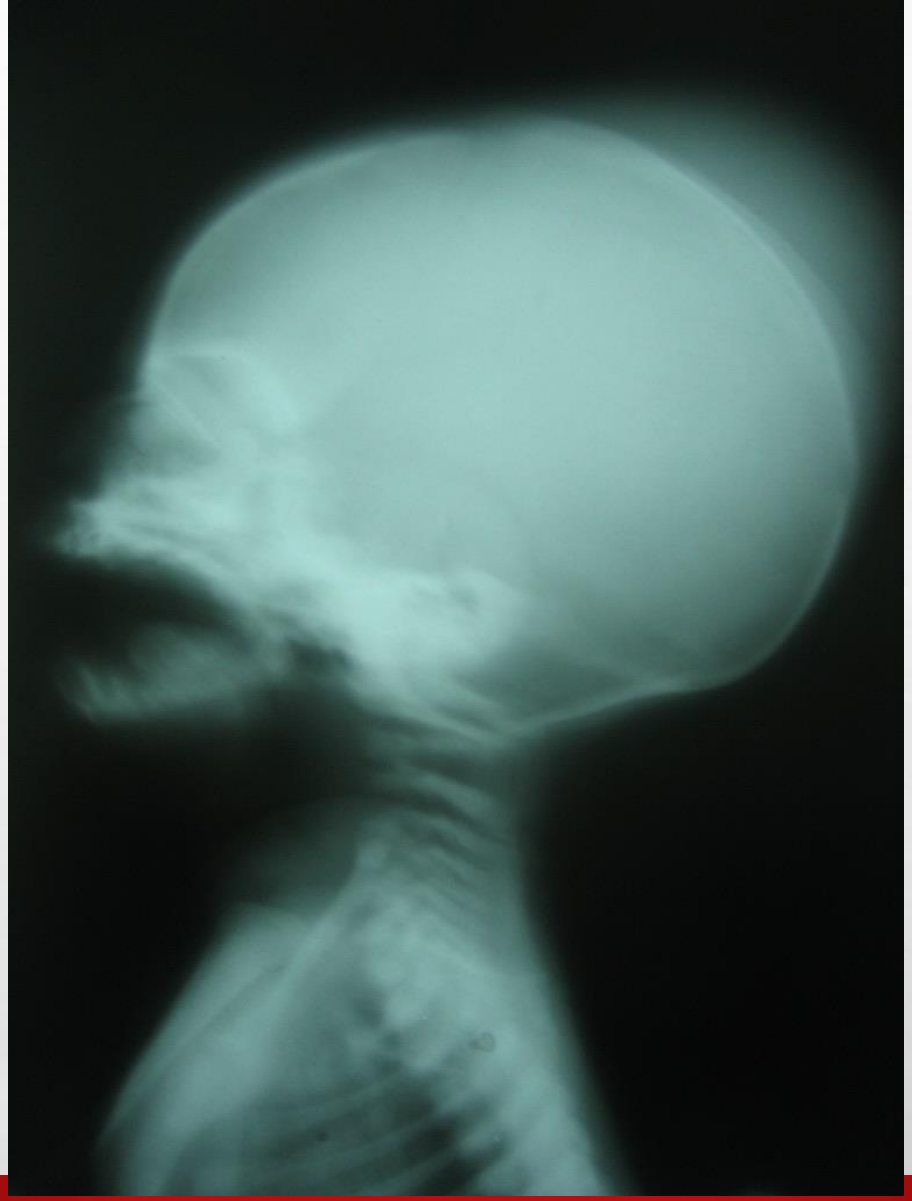

Increased ICP

SILVER BITTEN APPEARANCE

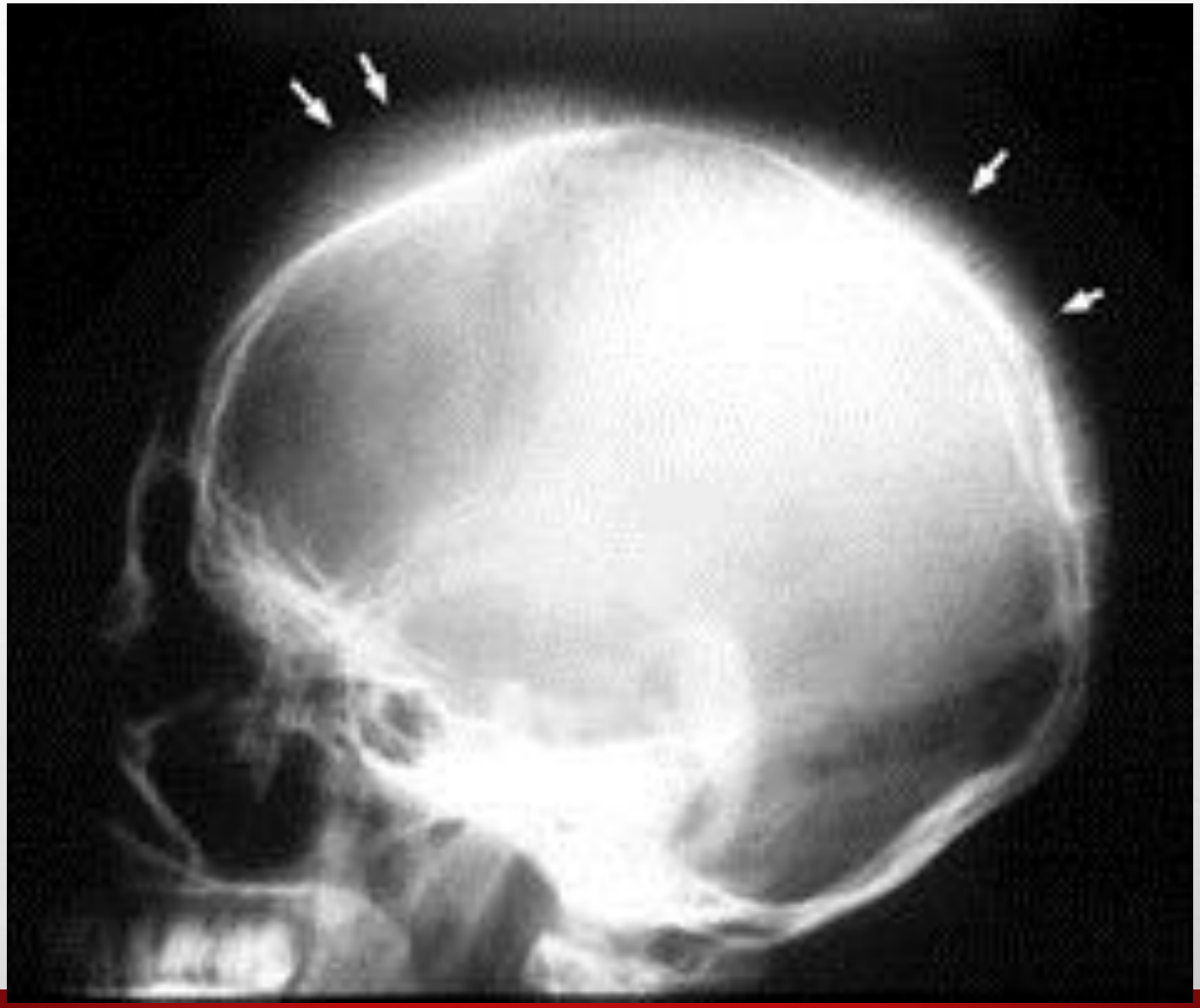

CH. HEMOLYTIC ANEMIA

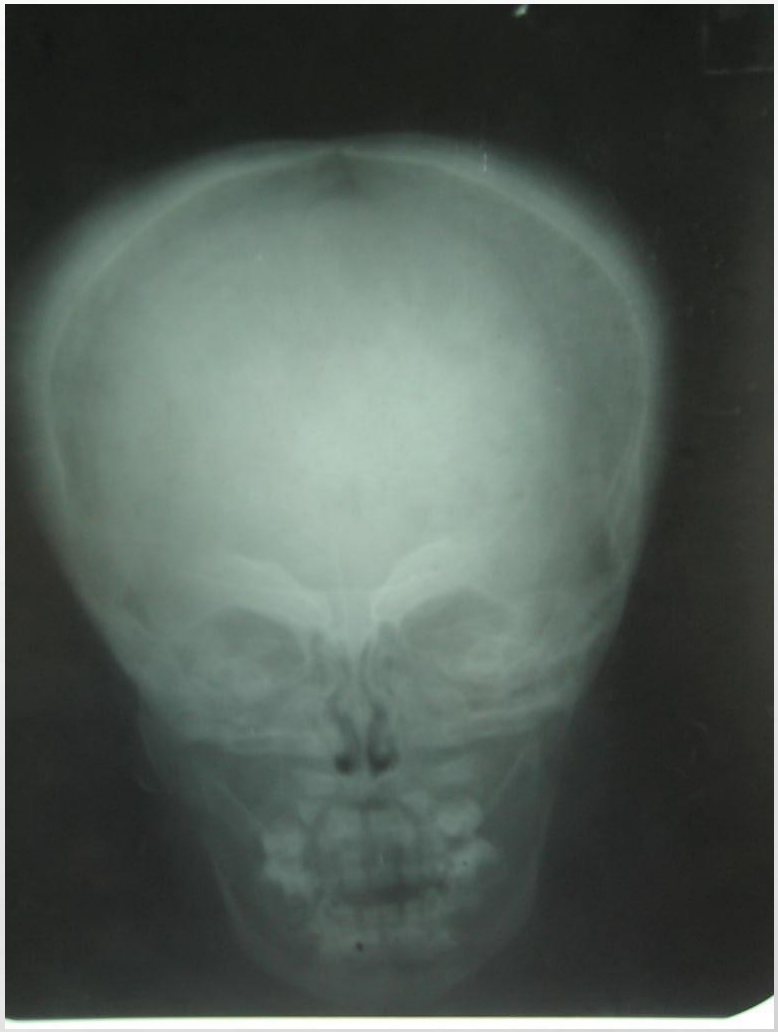

irregular shaped skull with silver beaten with closed sutures

tour shaped skull
closed sutures

MUCOPOLYSACCARIDOSIS

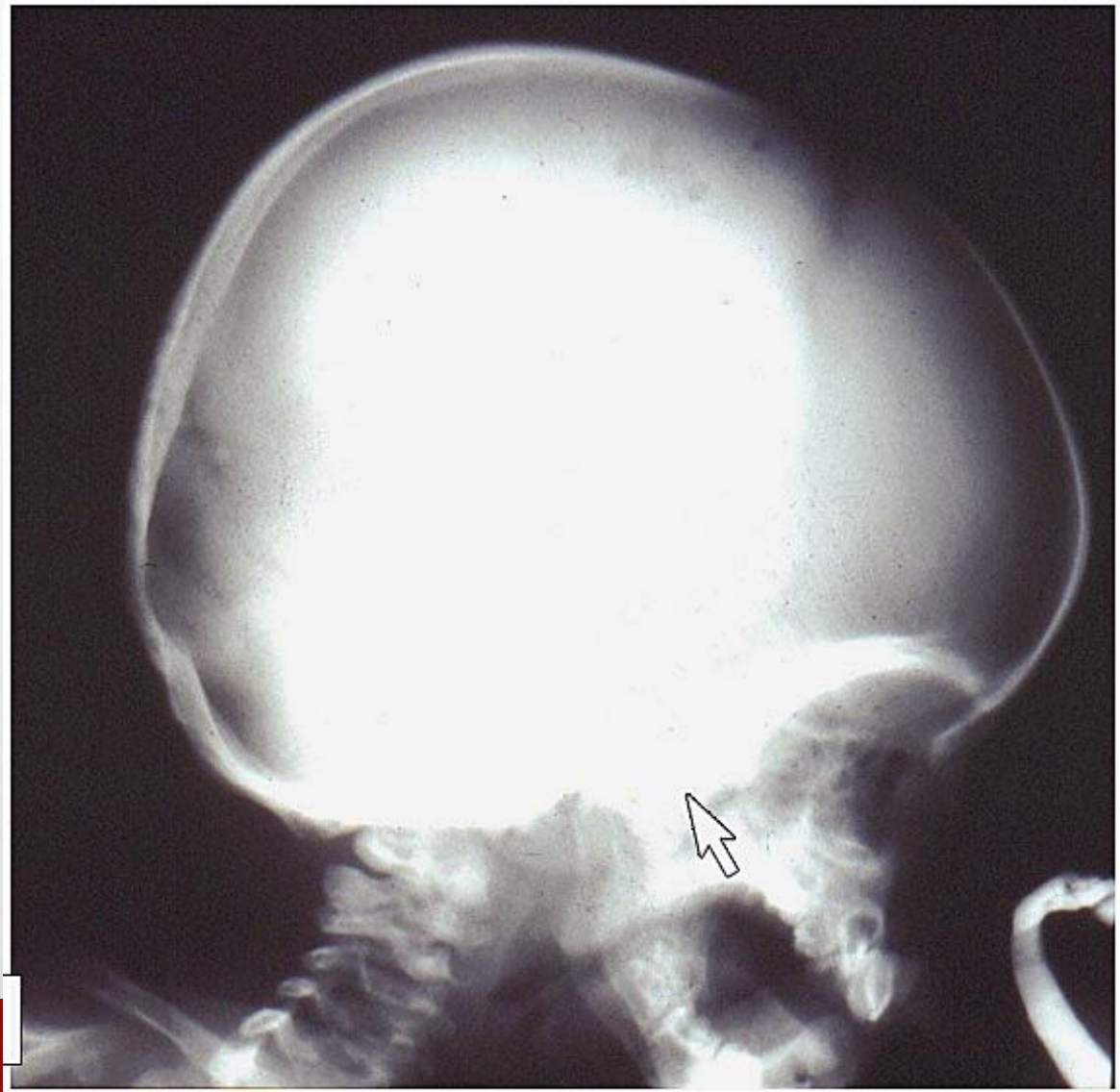

ENCEPHALOCELE

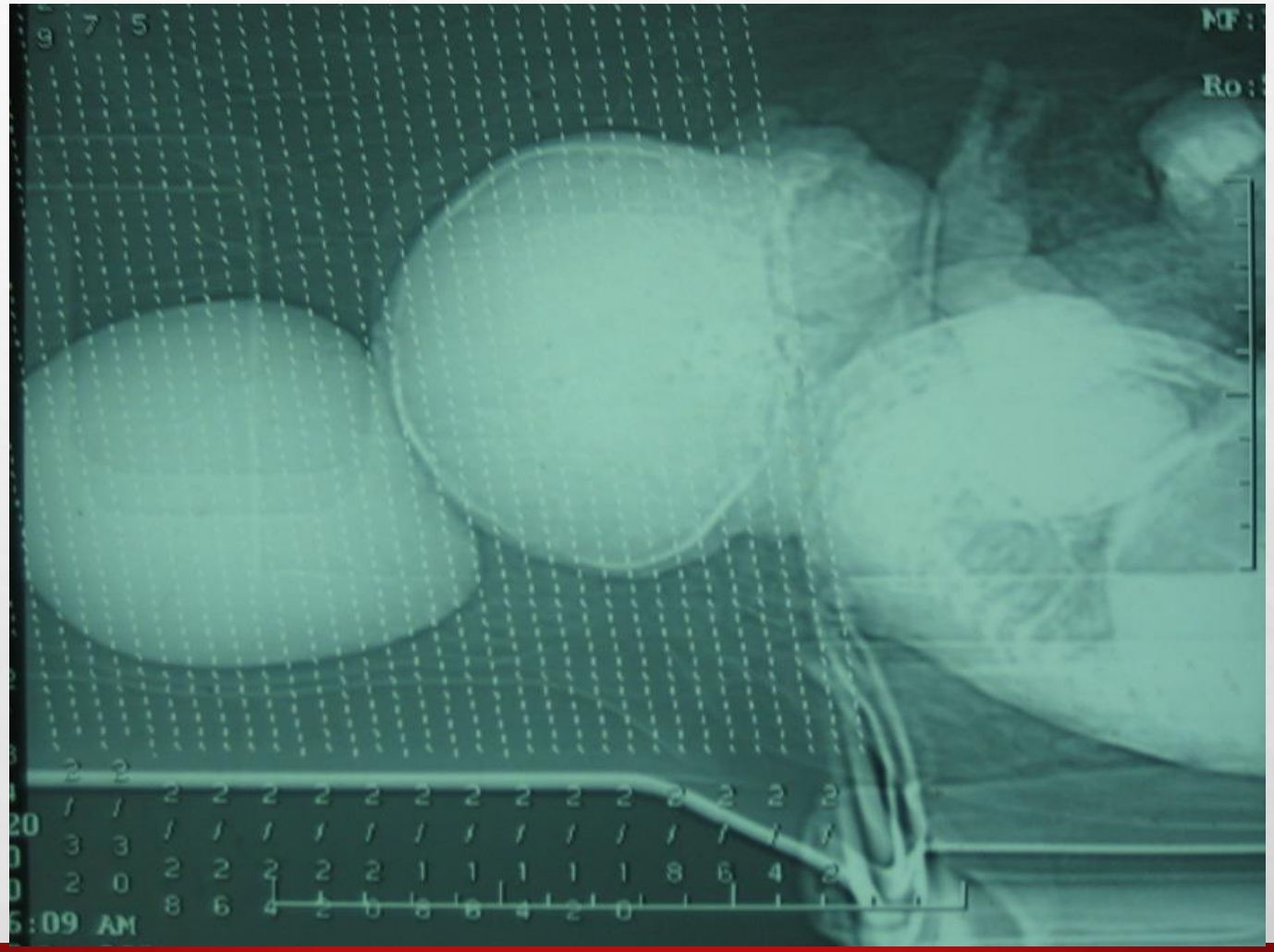

- FRACTURE SKULL

GIT

TOF

ACHALAZIA OF THE CARDIA

CONGENITAL PYLORIC STENOSIS

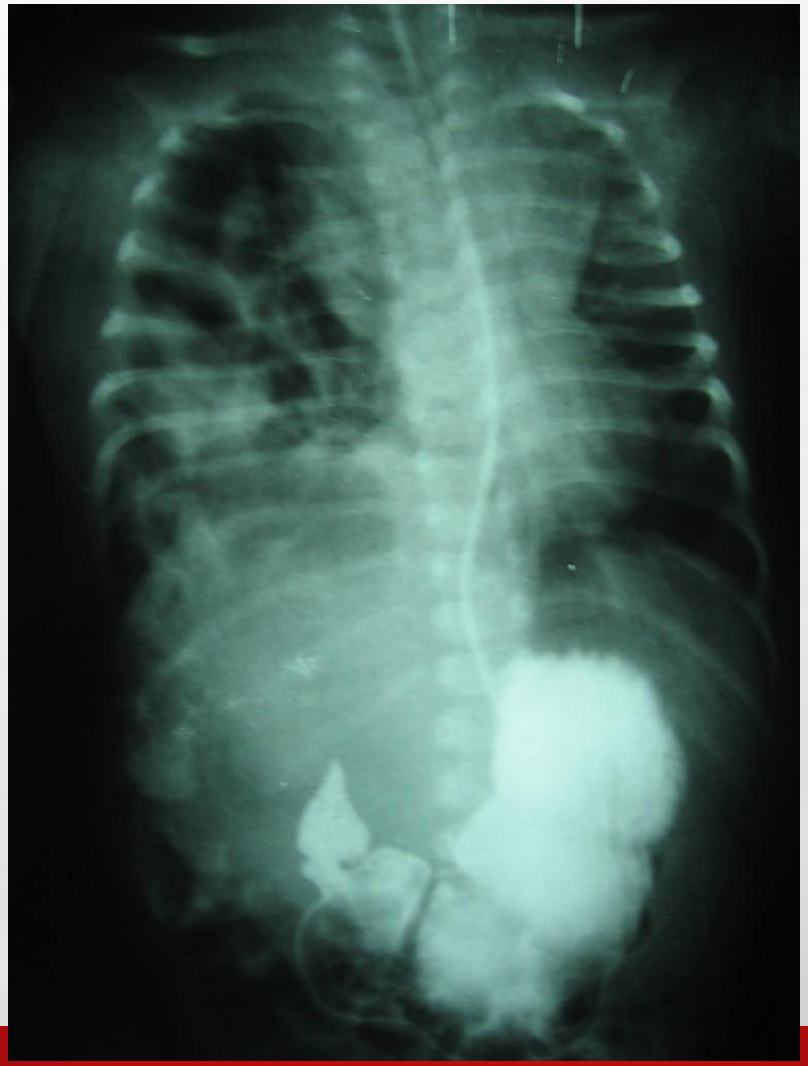

DUODENAL ATRESIA

DUODENAL ATRESIA

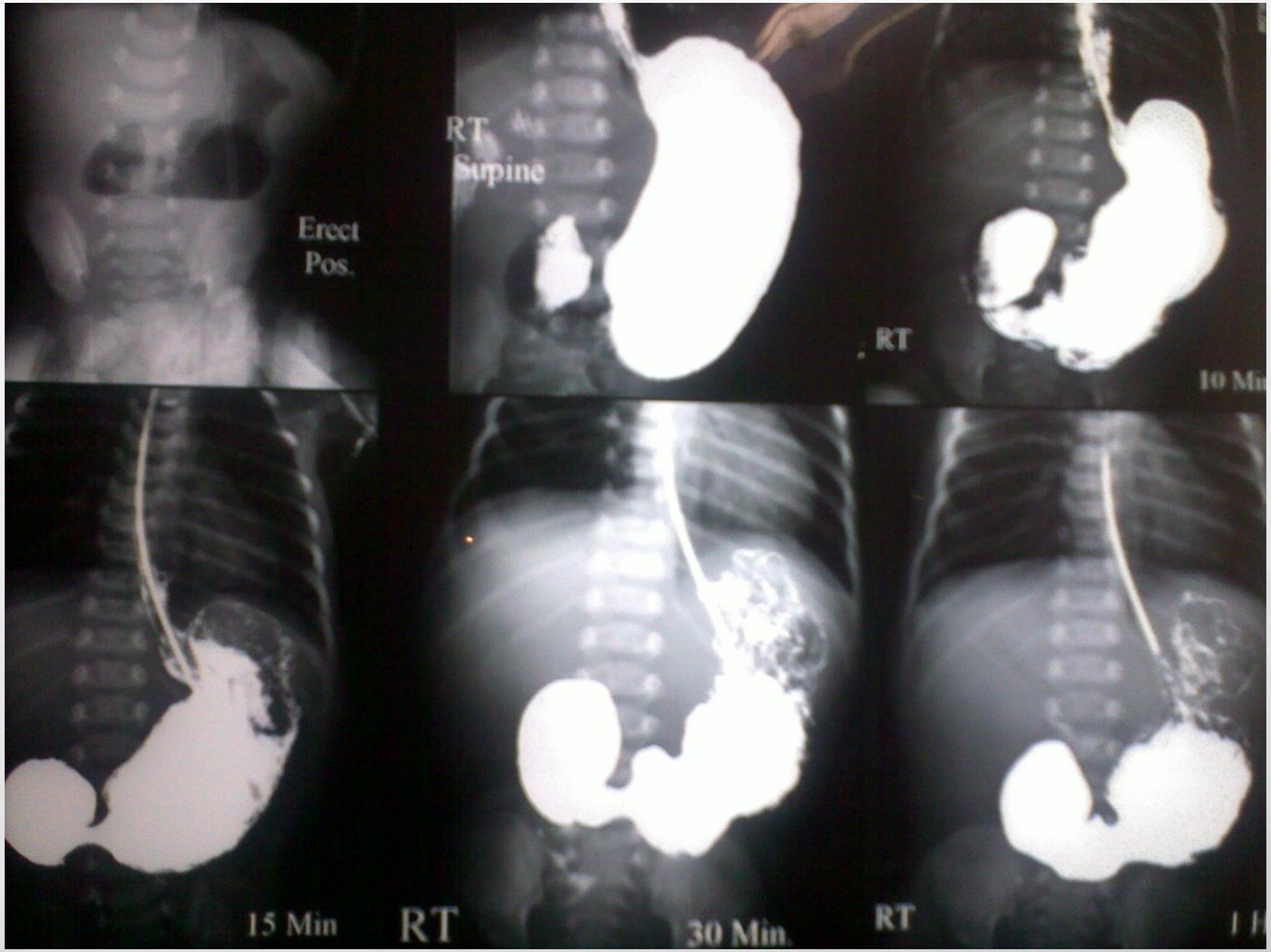

INTESTINAL OBSTRUCTION (FLUID LEVELS)

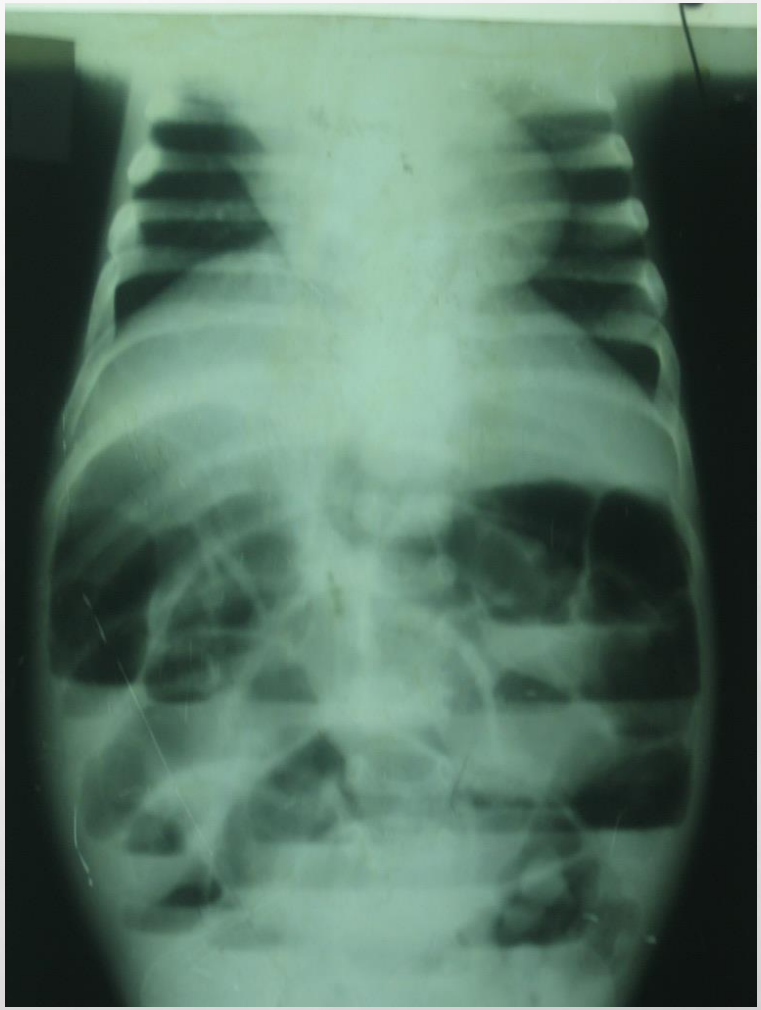

INTESTINAL OBSTRUCTION (FLUID LEVELS)

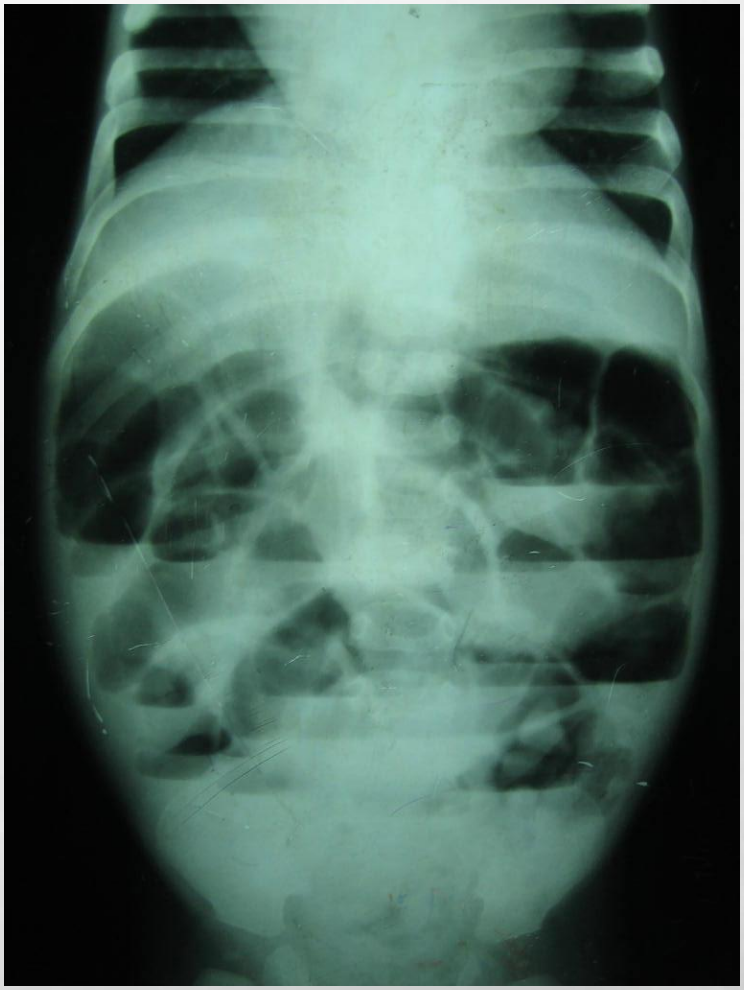

INTESTINAL OBSTRUCTION (FLUID LEVELS)

INTESTINAL PERFORATION

HIRSCH SPRUNG

HIRSCH SPRUNG ENEMA (1)

(1) Congenital aganglionic mega colon.

ESOPHAGEAL ATRESIA

CONGENITAL PYLORIC STENOSIS

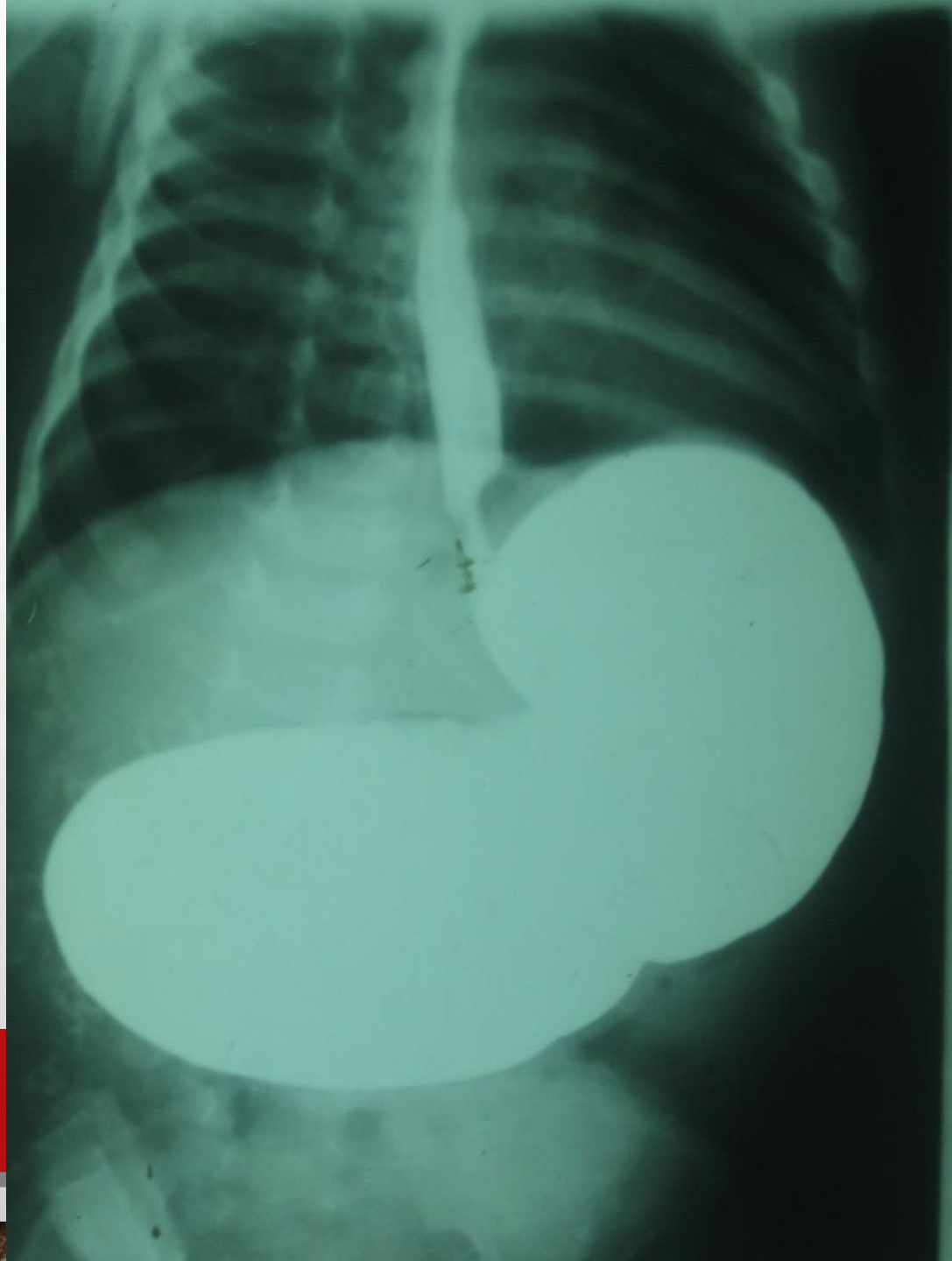

PYLORIC STENOSIS

P. STENOSIS

DOUBLE ESOPHAGUS

INTESTINAL OBSTRUCTION

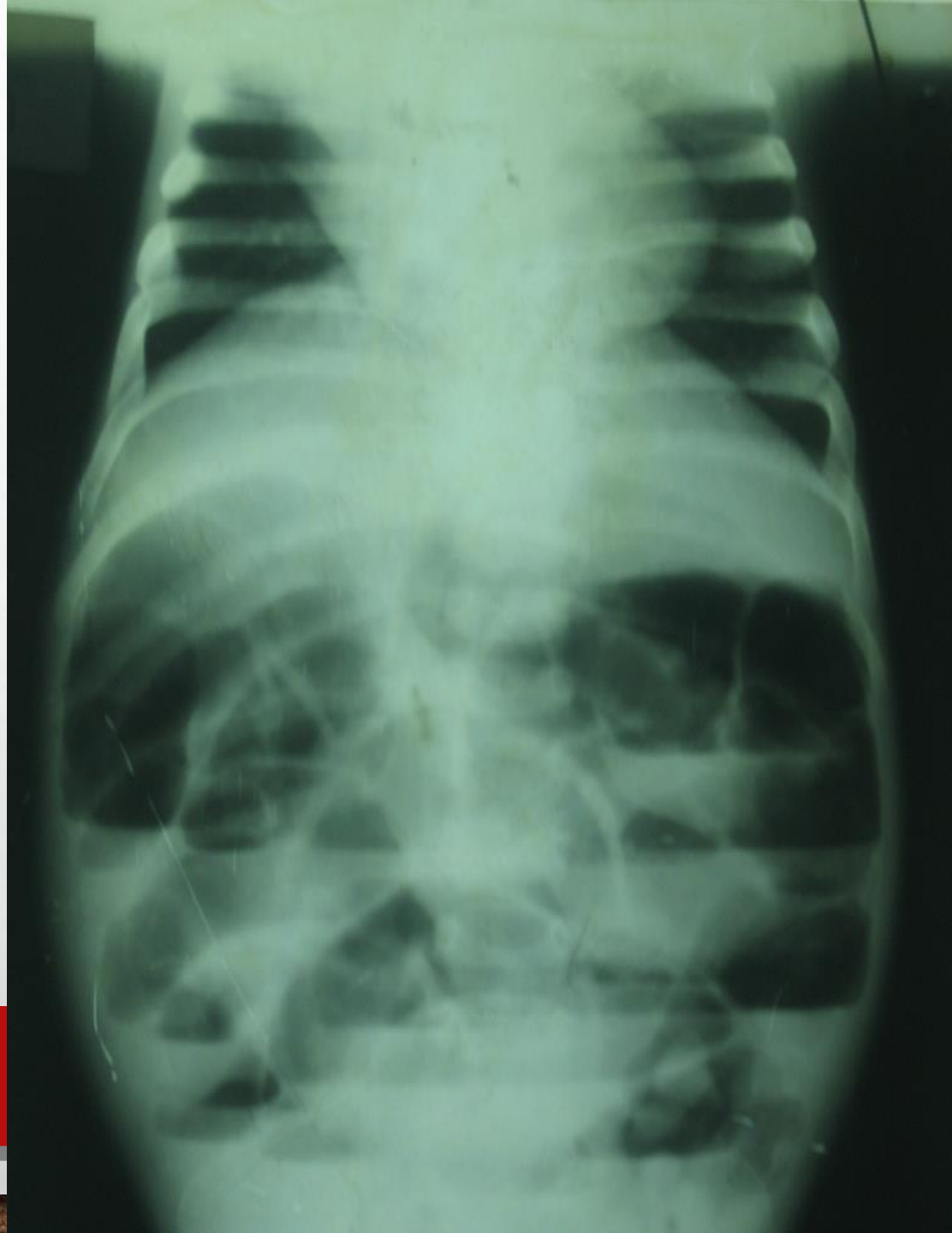

INTUSSUSCEPTIONS

HIRSH SPRUNG
BA. ENEMA

PARALYTIC ILEUS

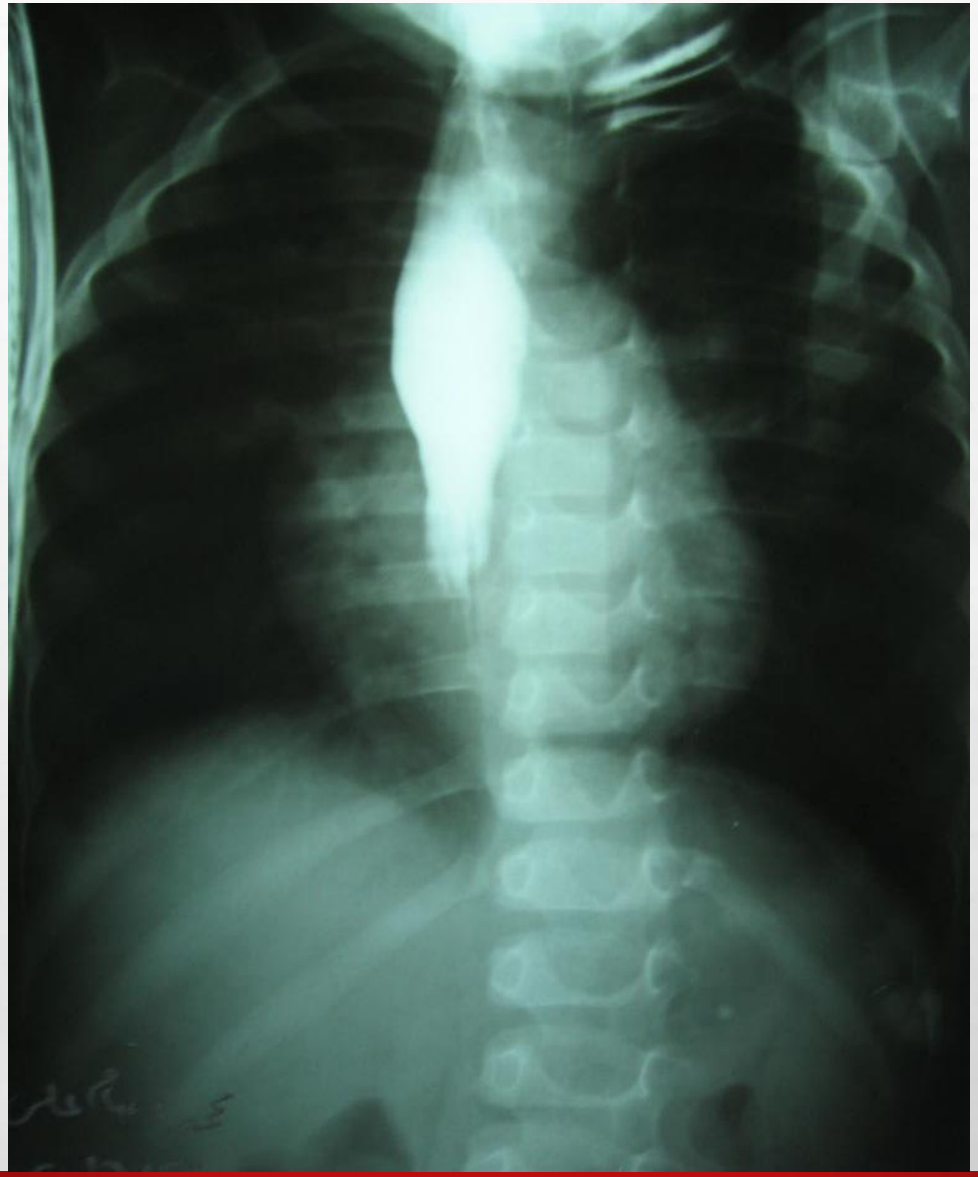

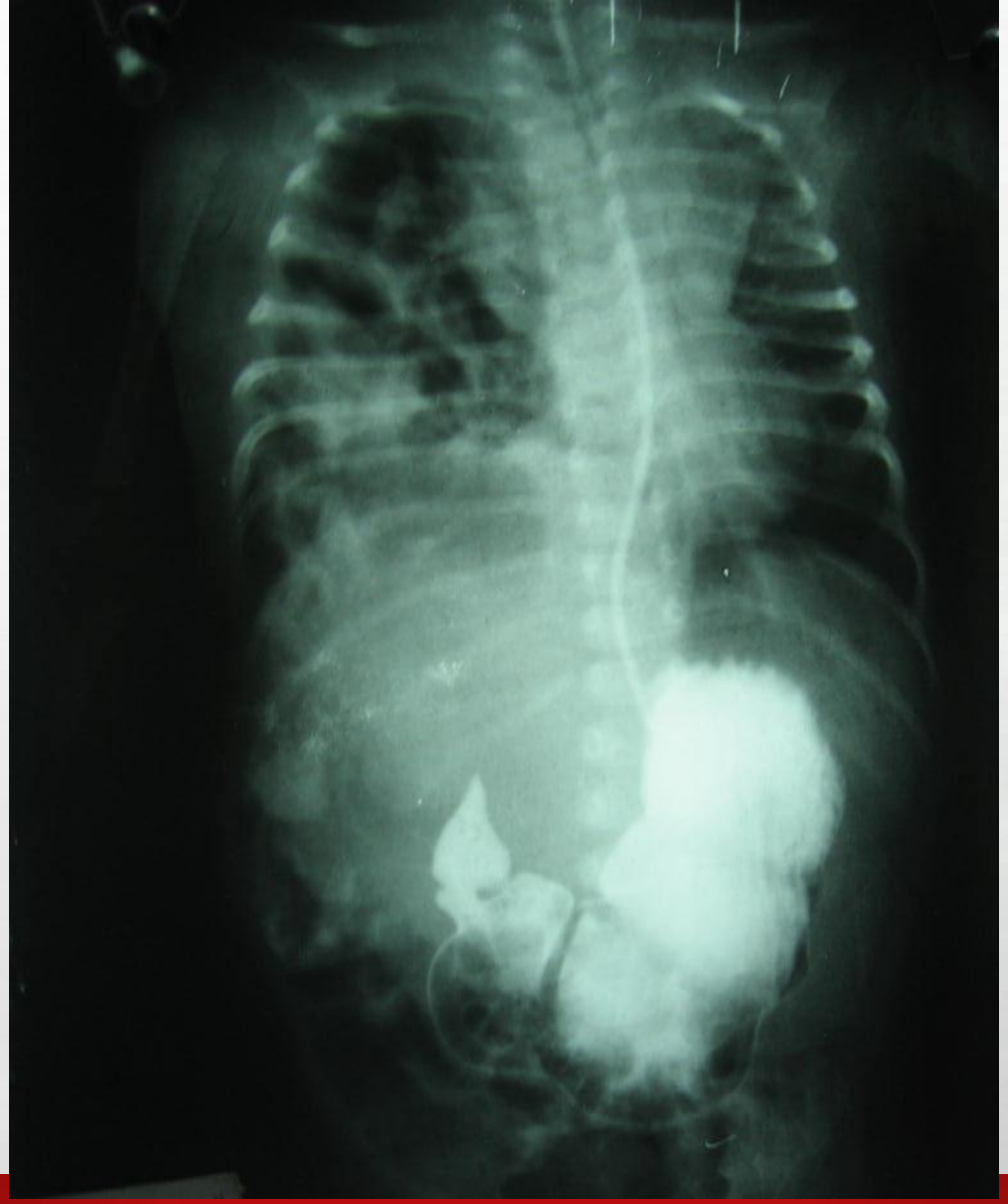

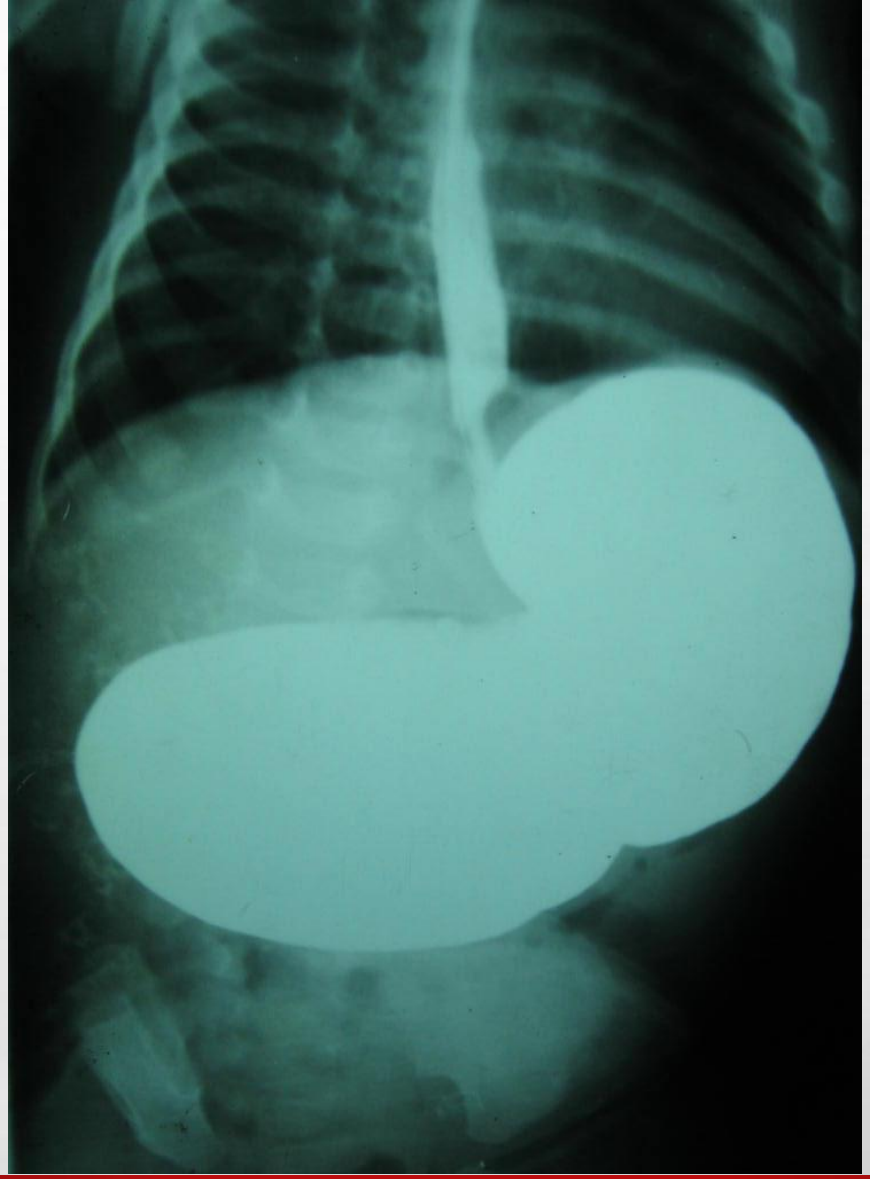

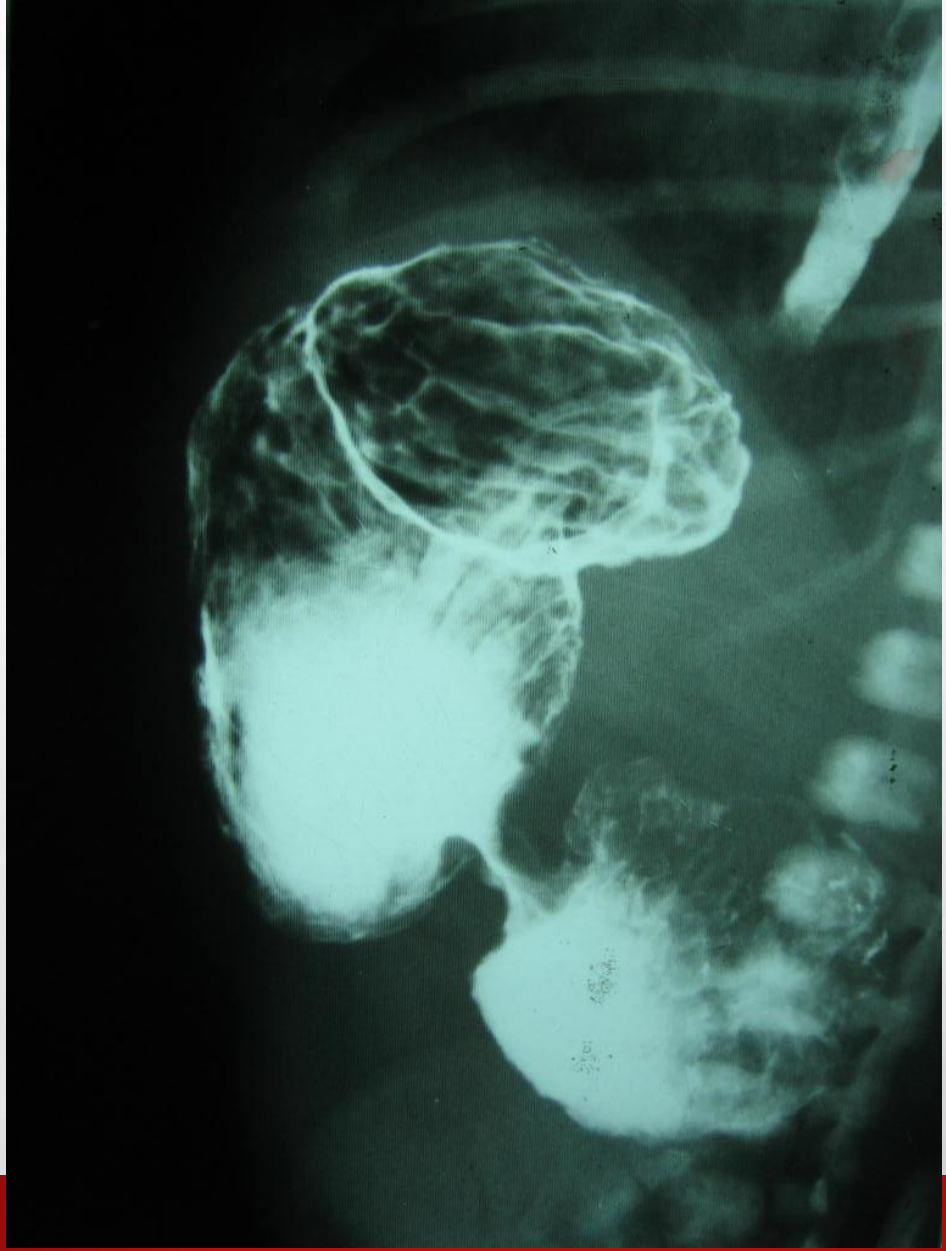

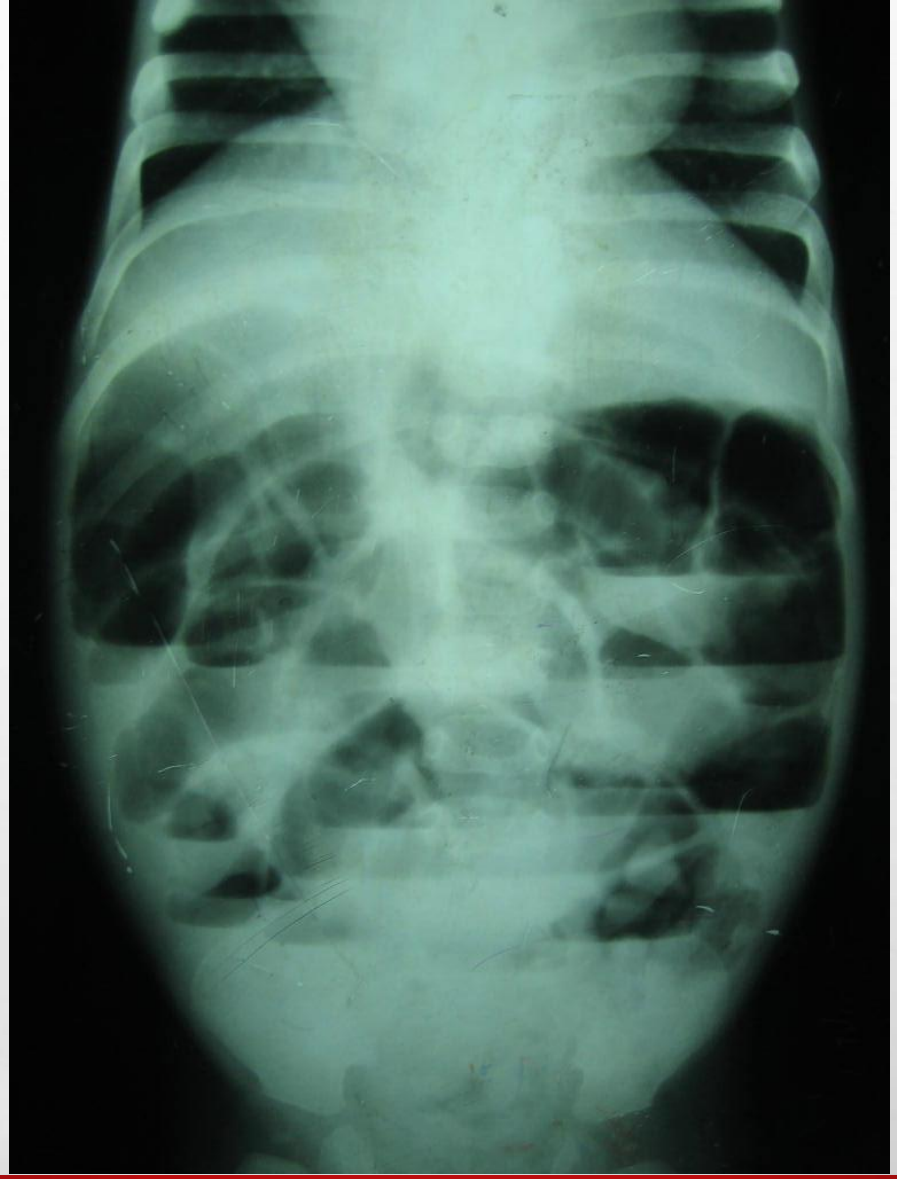

PNEUMO- INTESTINALIS

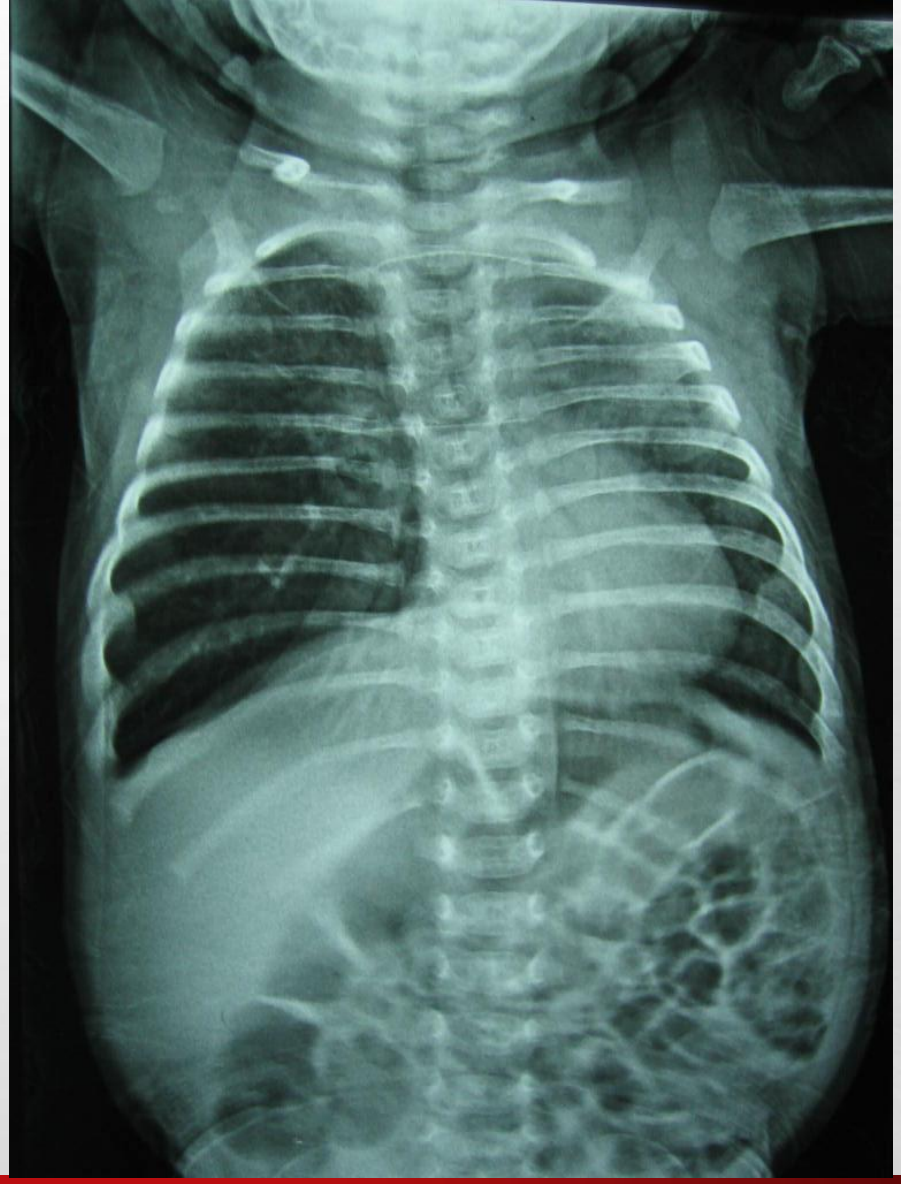

MEGA COLON

DIAPHRAGMATIC HERNIA

RENAL

RIGHT DOUBLE URETER

STAG HORN STONE

RIGHT HYDRO URETER & HYDRONEPHROSIS

BLADDER STONE

HOARSE SHOE KIDNEY

MEGA URETER

HIGH GRADE BILATERAL VESICO-URETERIC REFLUX

HIGH GRADE BILATERAL VESICOURETERIC REFLUX

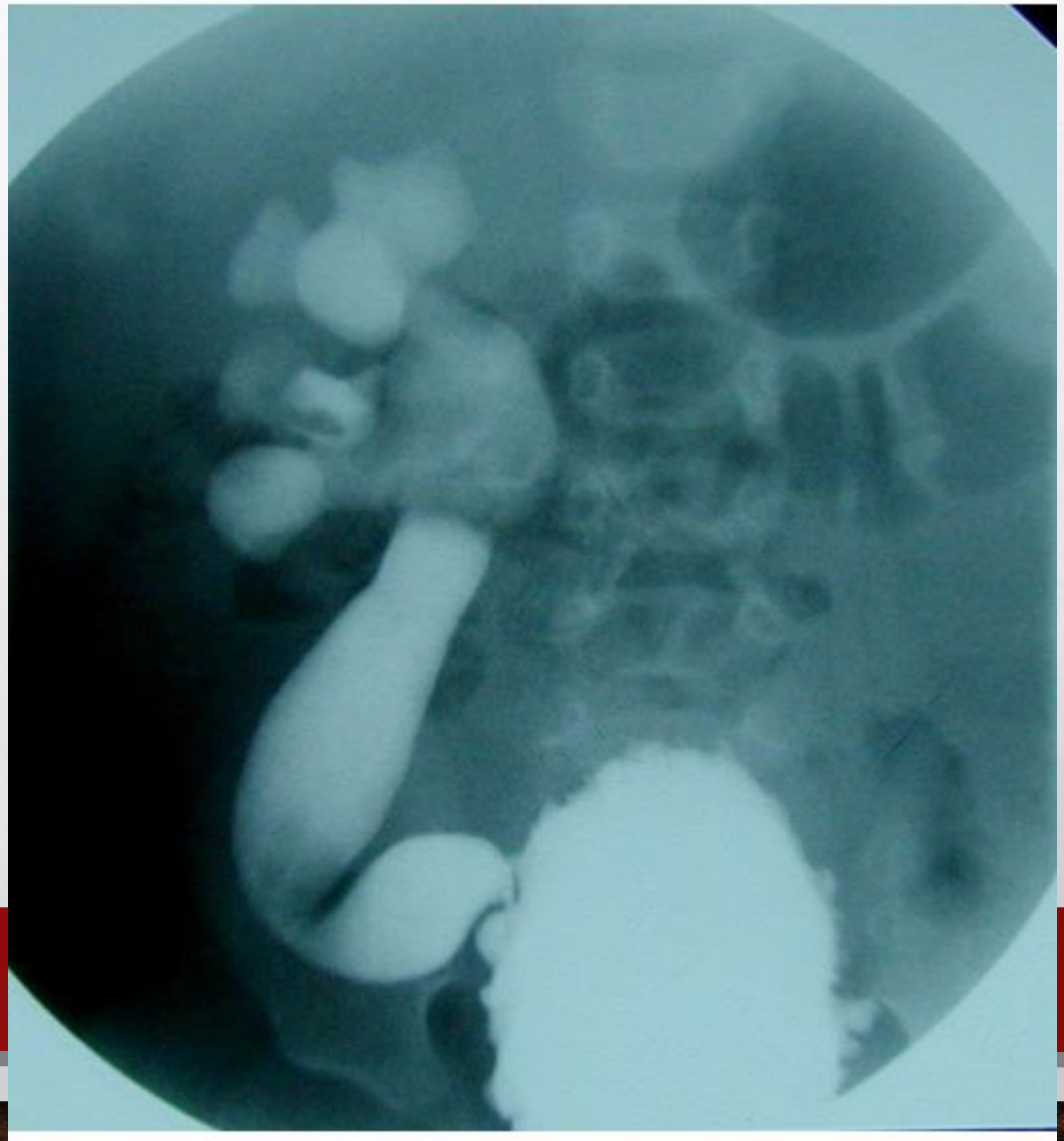

RENAL STONES

RT. KIDNEY

DOUBLE URETER

HYDRONEPHROSIS

GOOD LUCK

PROF. KAMAL EL TOHAMI